

## Engineering Analysis Shows Risk Of Wide Laminectomy

An uncommon, and little discussed, potential complication of Chiari decompression surgery is an anterior fracture of the C1 vertebra without major trauma. The top vertebra, also known as the axis because it supports the skull, is comprised of two bony arches (anterior/front and posterior/rear) and two bony masses on the sides (Fig 1). The skull rests in the two side depressions and part of the C2 vertebra, also known as the axis, extends through (Fig 2). The skull and the top two vertebrae work together to allow the head and neck to move forward and back, rotate, and tip laterally.

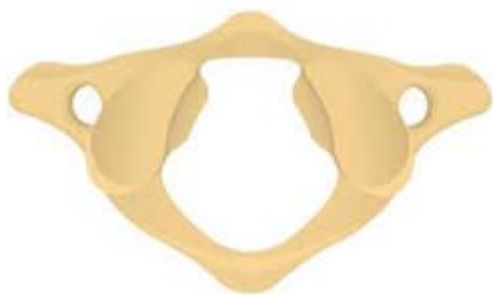

Fig 1

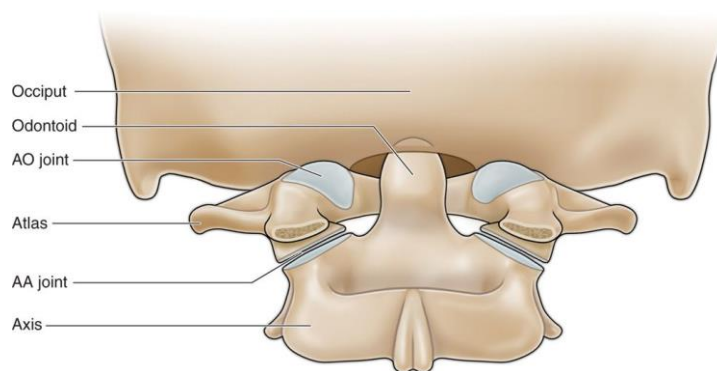


Fig 2

With Chiari, the cerebellar tonsils crowd this arrangement by not staying in the skull. Therefore, a standard part of Chiari decompression surgery is to remove some portion of the posterior arch of C1. This is known as a laminectomy. Note, if the herniation is large enough, some of C2 may also be removed. Removing the back arch of C1 changes the structural characteristics of the atlas and in some cases can lead to a fracture in the anterior arch without a major trauma.

While likely uncommon, exactly how often this occurs is not clear. There are a handful of case reports in the literature of patients experiencing acute neck pain after surgery which were then revealed to be fractures; but a fracture may also be asymptomatic and one paper estimated that it could happen in 10% or more of laminectomy cases.

Common sense would dictate that the more bone that is removed from the posterior side, the weaker the atlas would become overall, but there is no real standard for what the optimal amount to remove is. Rather surgeons must balance the benefits of decompression with the costs of removing too much in each case.

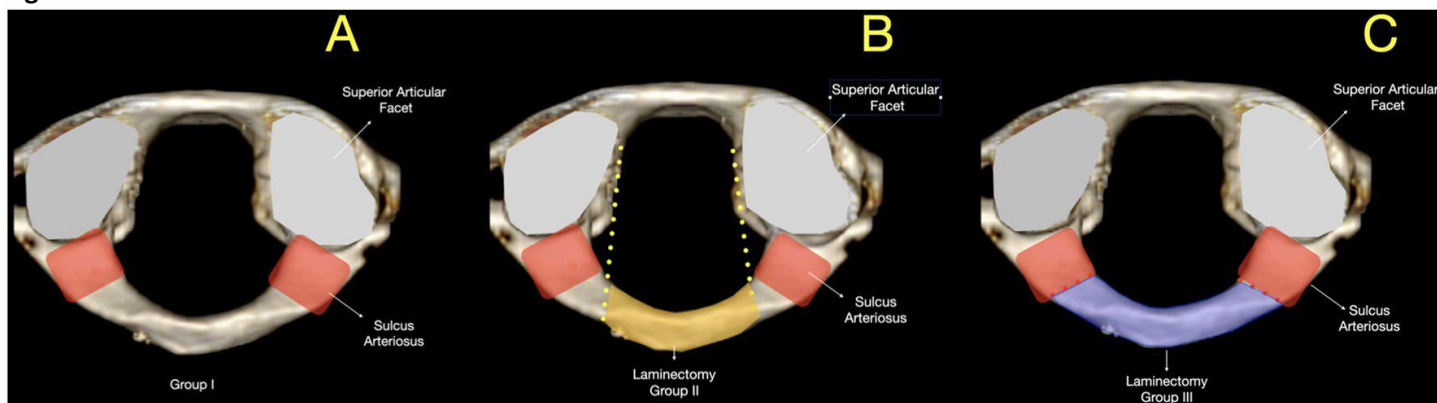
Finite element analysis is an engineering technique that uses calculations, models and simulations to predict and understand how an object might behave under various physical conditions. Recently, a group of engineers and a surgeon from Turkey employed Finite Element Analysis to quantify how much stress is put on the anterior arch of C1 as a result of removing different amounts of the posterior arch.

The research team looked at three cases (Fig 3). The first was an intact atlas, the second was a laminectomy where just the center part of the posterior arch was removed, and the third was a wider laminectomy. To simulate the load and stress on the atlas in each case, the team used available data on average head weight (5kg), bone properties, etc. to build a finite element model and calculated the resultant anterior load during standard head movements.

They found that the more limited laminectomy (Group 2) resulted in about a 40% increase in the load on the anterior arch relative to the non-surgical atlas. However, the more extensive laminectomy (Group 3) resulted in a 5 times increase

in the load on the anterior arch. In addition, the precise locations where the load was the highest corresponded to the fracture locations reported in the literature. The authors stress that this work is theoretical, but it does highlight the potential risks of a wide laminectomy.

**Fig 3**



**Source:** Maximum Safety Limits of Laminectomy of the C1 Vertebra for Chiari Malformation Surgery: A Finite Element Analysis. Kayalar AE, Yaltırık CK, Kalyoncu E, Bolat B, Temiztas BA, Etli MU, Çalışaneller AT, Naderi S. Indian J Orthop. 2023 Apr 1;57(6):884-890.

*Please consider a \$10 donation as Conquer Chiari's educational material is free to read, but not free to produce:*



<https://www.conquerchiari.org/donate>

*Conquer Chiari's research updates highlight and summarize interesting publications from the medical literature while providing background and context. The summaries do contain some medical terminology and assume a general understanding of Chiari. Introductory information and many more research articles can be found in the [Conquer Chiari Library](#).*

*Conquer Chiari is a 501(c)(3) public charity dedicated to improving the experiences and outcomes of Chiari patients through education, awareness and research.*