

## Regional Brain Tissue Displacement and Strain is Elevated in Subjects with CMI Compared to Healthy Controls: A Study Using DENSE MRI

BLAISE NWOTCHOUANG, MAGGIE S. EPPELHEIMER, SOROUGH HEIDARI PAHLAVIAN, JACK W. BARROW, DANIEL L. BARROW, DEQIANG QIU, PHILIP A. ALLEN, JOHN N. OSHINSKI, ROUZBEH AMINI, FRANCIS LOTH

### Purpose

DENSE is an advanced MRI technique that can measure even small amounts of tissue motion extremely accurately. This study used DENSE MRI to compare the motion in different brain regions of Chiari patients compared to healthy controls and to calculate the associated strain that these brain regions experience during the natural cardiac cycle.

### Methods

Forty-three CMI subjects and 25 healthy controls underwent DENSE MRI scans to measure the displacement (movement) in seven different brain regions. From this, strain (stretching and compression as a percent of the length) was calculated. Selected symptom related data was also collected from the CMI subjects.

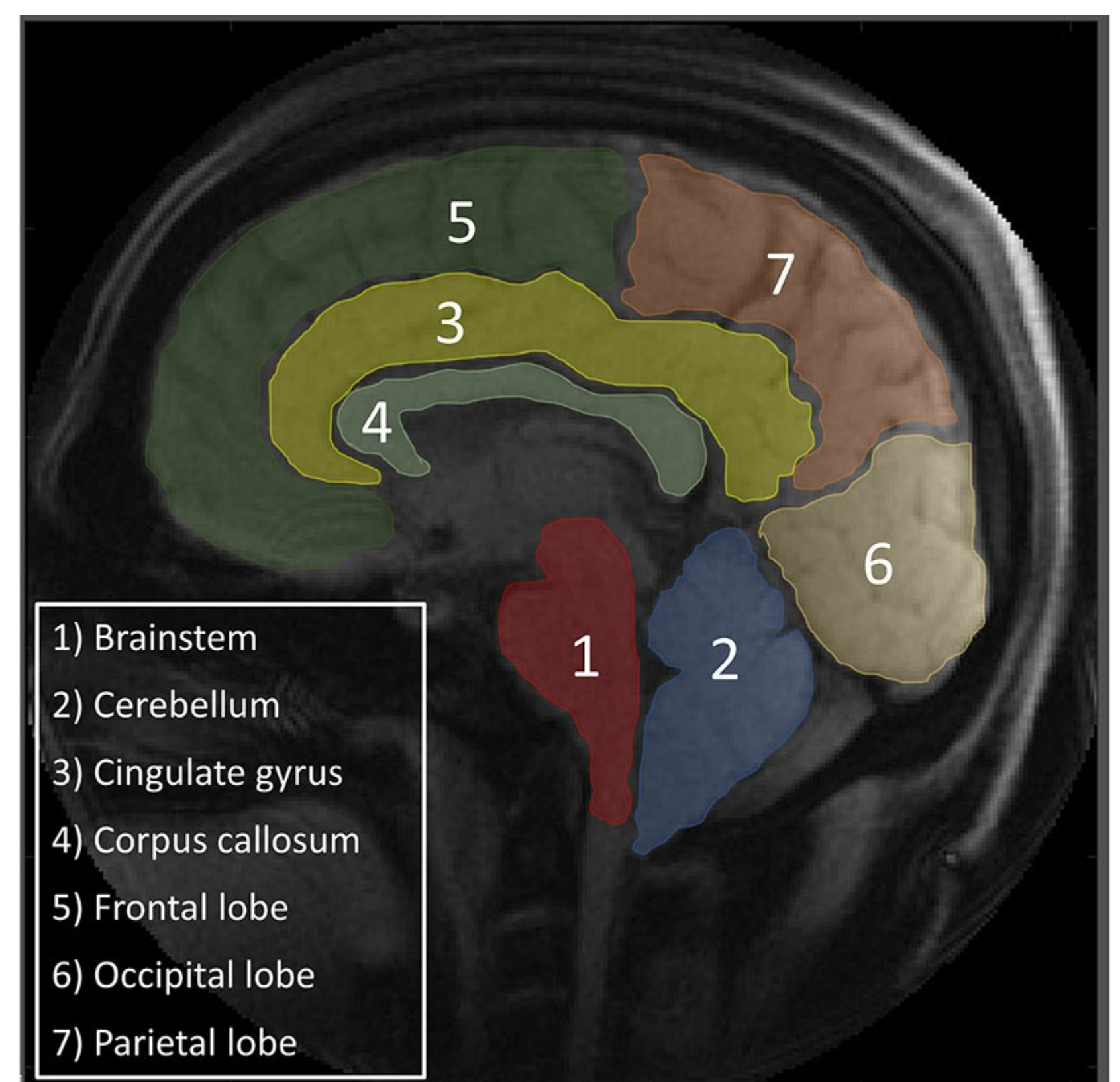
### Results

Mean displacements in the cerebellum and brainstem were 106 and 64% higher, respectively, in CMI subjects than controls. Mean compression and extension strains in the cerebellum were 52 and 50% higher, respectively, in CMI subjects. Brainstem mean extension strain was 41% higher in CMI subjects, but compression strain was not significantly different. The excess movement in both the cerebellum and brainstem occurred primarily in the lower regions of the structures (see Diagram). The other brain structures revealed no significant differences between the groups. For the CMI subjects, the strain was not shown to be linked to specific symptoms.

### Conclusions

This study used an advanced MRI technique to show that the cerebellums and brainstems of Chiari patients move significantly more during the cardiac cycle than they do in healthy controls. There is also excessive stretching and compression of the cerebellum and brainstem tissue in Chiari patients. More research is required to understand why this occurs, to quantify the movement and strain during exertion, to determine what levels of strain result in damage and symptoms, and to see if DENSE would be a useful tool for aiding in diagnosis and surgical decision making.

### Seven Brain Region Examined Using DENSE MRI



### Displacement Maps of the Cerebellum and Brainstem (CMI vs Control)

