


Topics: CT Reveals Major Clivus Changes; Depression & Anxiety; Chiari Men vs Women; 3D Printed Part for Chiari Surgery

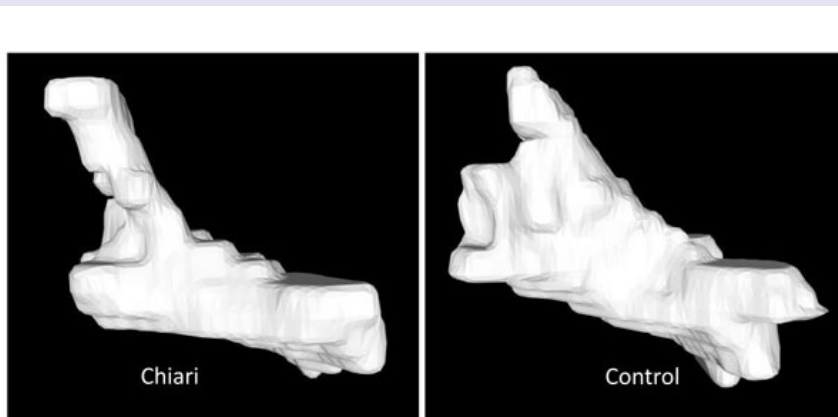
Conquer Chiari's monthly research updates highlight and summarize interesting publications from the medical literature while providing background and context. The summaries do contain some medical terminology and assume a general understanding of Chiari. Introductory information about Chiari, plus many more research articles, can be found at www.conquerchiari.org.

 Download the June Research Update PDF

Major Clivus Changes in Chiari Discovered on CT

The clivus bone is part of the skull base which slopes up and backwards from the foramen magnum in the middle of the skull. In fact, clivus means "slope" in Latin. The pons, which is part of the brainstem, essentially sits on the clivus and the pituitary gland is located above the top of the clivus. Previous research from the Conquer Chiari Research Center (CCRC) has shown that the two-dimensional length of the clivus is significantly shorter in Chiari patients. A second study found that the short clivus is true across Chiari patients with related conditions such as EDS and pseudotumor. Now, a third study from the CCRC has found that the clivus bone in Chiari patients is even more dramatically different in three dimensions. Bones are hard to measure on MRI, but pulling from the Chiari1000 the CCRC researchers used CT images which patients had submitted to compare the volume, surface area, linear dimensions, and spatial positions of the clivus bones of 30 adult female Chiari patients to age and BMI matched controls. After using special software to make sure all the images were aligned in the same way, they found that not only was the 2D length shorter in the Chiari group, but height, width, and thickness were also reduced. In fact, the overall clivus volume of the Chiari group was 31% smaller on average in the Chiari group. This difference can be readily seen in the image below. The researchers also looked at the sphenoid sinus which is the sinus cavity directly opposite the brainstem on the other side of the clivus. They found that the sphenoid sinus was 38% larger in the Chiari group. Finally, the team looked at the area of the sella turcica which is a saddle like structure at the top of the clivus where the pituitary sits. They found that in the Chiari group, this area was reduced by 27%. It is not clear what this effect this reduced area would have on the function of the pituitary in Chiari patients. In fact, the implications of all of these dramatic findings are not immediately

NOTE: If you are a Chiari patient with CT images and are willing to share them for research, please email dloth@uakron.edu.



SOURCE: Three-Dimensional CT Morphometric Image Analysis of the Clivus and Sphenoid Sinus in Chiari Malformation Type I. Nwotchouang BST, Eppelheimer MS, Bishop P, Biswas D, Andronowski JM, Bapuraj JR, Frim D, Labuda R, Amini R, Loth F. *Ann Biomed Eng.* 2019 Jun 11
Chiari vs Control Image courtesy of Conquer Chiari Research Center

Psychological Effects of Chiari are Profound

The Chiari1000 project is collecting data in several ways: self-report questionnaires, validated neuropsychological scales, imaging, and biological samples such as saliva and blood. Previously, the CCRC has published several studies focused on the imaging data collected (like the study summarized above) and now they have also published a study utilizing the neuropsychological scales. The scales in the Chiari1000 are widely accepted tools to assess things like depression, anxiety, illness attitude, pain and disability. While there are some papers in the Chiari literature that reference patient self-reported depression (which can be up to 50%), this is the first large-scale assessment of the psychological health of Chiari patients, and unfortunately the results are alarming and paint a grim picture of the toll that dealing with Chiari has on people. Specifically, the study included over 1100 adult patients, with 53% having undergone decompression surgery, and 47% not having surgery. A shocking 44% of Chiari patients scored at moderate to severe levels of depression. This compares to a national average of 10.4% of people who experienced these levels of depression in the previous 12 months. Similarly, 40% of the patients scored at the moderate to severe level of anxiety, compared to a national average of 19%. Finally, an incredible 80% scored at the moderate or worse level for disability. Interestingly, the differences between the surgical and non-surgical groups were fairly small. However it is not clear if the surgical patients were even worse off before surgery, so it is difficult to draw any conclusions about the effectiveness of surgery in improving these issues. It is also not clear why the depression and anxiety numbers are so high. In other words is the pressure or CSF disruption somehow directly causing these issues or are they a by-product of dealing with chronic pain and disability? Although the number of participants is very large (over 1,000) it should be noted that because of the nature of the Chiari1000 the sample may not reflect the general Chiari population and may be skewed towards patients with worse outcomes and chronic symptoms. However, this data clearly shows that a large portion of Chiari patients would likely benefit from some type of intervention beyond surgery

SOURCE: *An examination of pain, disability, and the psychological correlates of Chiari Malformation pre- and post-surgical correction.* Garcia MA, Allen PA, Li X, Houston JR, Loth F, Labuda R, Delahanty DL. *Disabil Health J.* 2019 May 21

Chiari Men & Women Have Similar Skull/Brain Anatomy

In another morphometrics focused publication based on images from the Chiari1000, CCRC researchers looked at gender differences in Chiari patients. Specifically, they examined posterior fossa measurements for four groups of 26 adults: Male Chiari patients, Male Controls, Female Chiari Patients, and Female Controls. Both of the control groups were matched by age, gender, and BMI to the respective Chiari groups. Perhaps not surprisingly, they found a similar pattern of morphometric differences in the men as was previously reported (and found again) in the women. Namely, a significantly shortened clivus bone, abnormal clivus angle, and the entire hindbrain (cerebellum, brainstem, corpus callosum being lower in the skull. However, they also found that many of these differences were more pronounced in the male group than the female group. For example, the clivus bone of the female Chiari patients was on average 3mm shorter than the female control group average. But the difference of the clivus bone length for the male patient group compared to the male control group was 5mm. Overall, the findings give the impression that male Chiari patients tend to have more extreme anatomical variations than female Chiari patients. As the researchers point out, this is surprising because it is estimated that 70% (or more) of adult Chiari patients are female.

SOURCE: *Evidence for sex differences in morphological abnormalities in type I Chiari malformation.* Houston JR, Allen NJ, Eppelheimer MS, Bapuraj JR, Biswas D, Allen PA, Vorster SJ, Luciano MG, Loth F. *Neuroradiol J.* 2019 Jun 18.

Surgeons Use 3D Printing to Create Patient Specific Bone Replacement

Surgeons from the Netherlands have reported on the feasibility of using 3D printed molds for posterior fossa reconstruction as part of Chiari surgery. Currently some surgeons use a titanium mesh to replace the piece of skull that is removed during surgery. This is thought to help prevent dural scarring and reduce the chance of symptom recurrence. In this report, the surgeons developed a surgical planning software tool which used patient specific CT scans to map out the craniectomy (bone removal) and design a mold for the reconstruction. The mold was then created using a 3D printer and filled during surgery with a type of bone cement. The reconstruction piece was attached to the skulls using screws. The surgeons developed and refined the software and mold printing using CT scans from past patients and then used the technique successfully on 3 patients. Post-surgical CT scans showed the accuracy of the reconstruction versus what was planned. The surgeons stress this was only a feasibility study and any benefits of this technique over titanium mesh would have to be evaluated. However, it is exciting to see the surgical community applying the latest technology to Chiari.

SOURCE: *3D-printed PMMA casting molds for posterior fossa reconstruction in the surgical treatment of Chiari I malformation: technical note and illustrative cases.* Pijpker PAJ, Wagemakers M, Kraeima J, Vergeer RA, Kuijlen JMA, Groen RJM. *World Neurosurg.* 2019 May 28.

Conquer Chiari is a 501(c)(3) public charity dedicated to improving the experiences and outcomes of Chiari patients through education, awareness and research.

[Home](#) | [About Us](#) | [Email](#) | [Donate](#) | [Get Involved](#) | [Privacy Policy](#)

Disclaimer: This publication is intended for informational purposes only and may or may not apply to you. The editor and publisher are not doctors and are not engaged in providing medical advice. Always consult a qualified professional for medical care. This publication does not endorse any doctors, procedures, or products.