

Quantification of Changes in Brain Morphology Following Decompression Surgery in Chiari Type I Malformation

Maggie S. Eppelheimer, Audrey M. Braun, Dipankar Biswas, James R. Houston, Philip A. Allen, Jayapalli Rajiv Bapuraj, Richard Labuda, Dorothy M. Loth, Francis Loth

Purpose

Historically, a quantitative morphometric comparison of a patient's MRI pre- and post-surgery has been difficult because a key landmark that is used, the end of the occipital bone (opisthion) is removed as part of the procedure. Enabling the quantitative comparison of morphometric measures pre- and post-surgery may aid in the selection of patients for surgery, surgical planning, and evaluation of surgical success. As part of our larger morphometric research efforts, we developed a novel technique which allows for such comparisons.

Methods

Fifty-nine morphological parameters were evaluated using 42 T1-weighted MR images of Chiari patients before and after surgery, and 42 female healthy controls. Custom software was used to obtain these 59 parameters in the posterior cranial fossa, craniocervical, and intracranial region in the midsagittal plane. Pre- and post-surgery morphological parameters were compared through the development of a novel technique to re-establish a key reference point (opisthion) that is removed during decompression surgery (a). This technique was validated using multiple sets of pre-surgical images and comparing the measurements with those obtained with the standard software.

Results

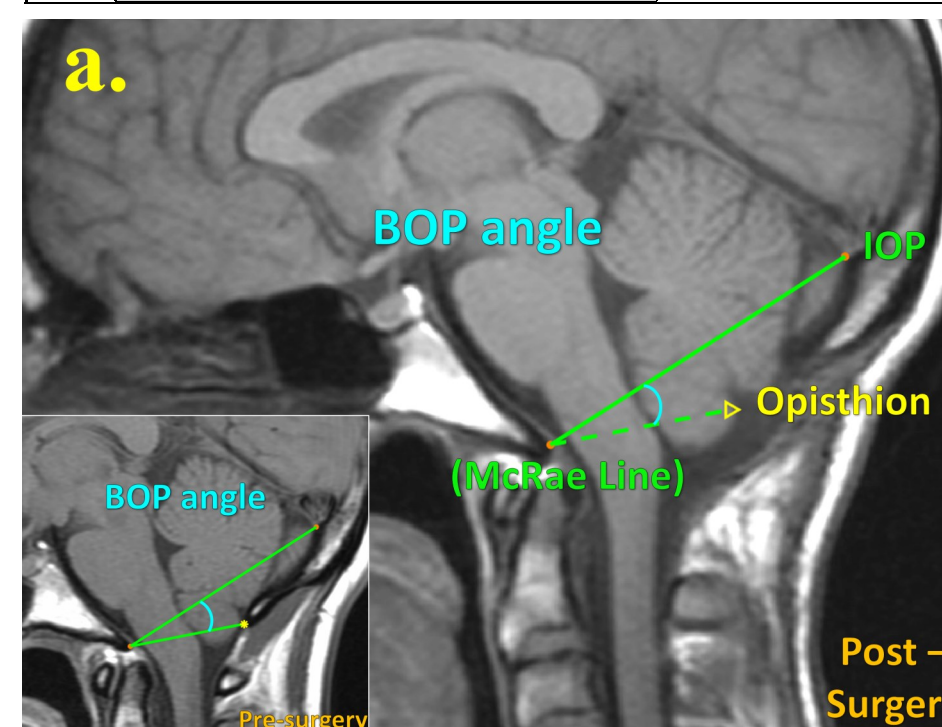
We found that the cerebellum height was 2.8 millimeters shorter after surgery, primarily due to the reduction of the tonsils. Additionally, we found that the cerebrospinal fluid spaces inferior and posterior to the cerebellum increased by 1.5- and 5-fold after surgery. This increase of cerebrospinal fluid spaces was primarily impacted by a 60% reduction of the occipital bone length, on average, after surgery (mean: 16.9 ± 8.8 mm). Through the evaluation of four different angles that quantify the relationship between the cerebellum and different osseous and soft tissue structures, we found that the cerebellum rotated 2-4 degrees counter-clockwise after surgery.

Conclusions

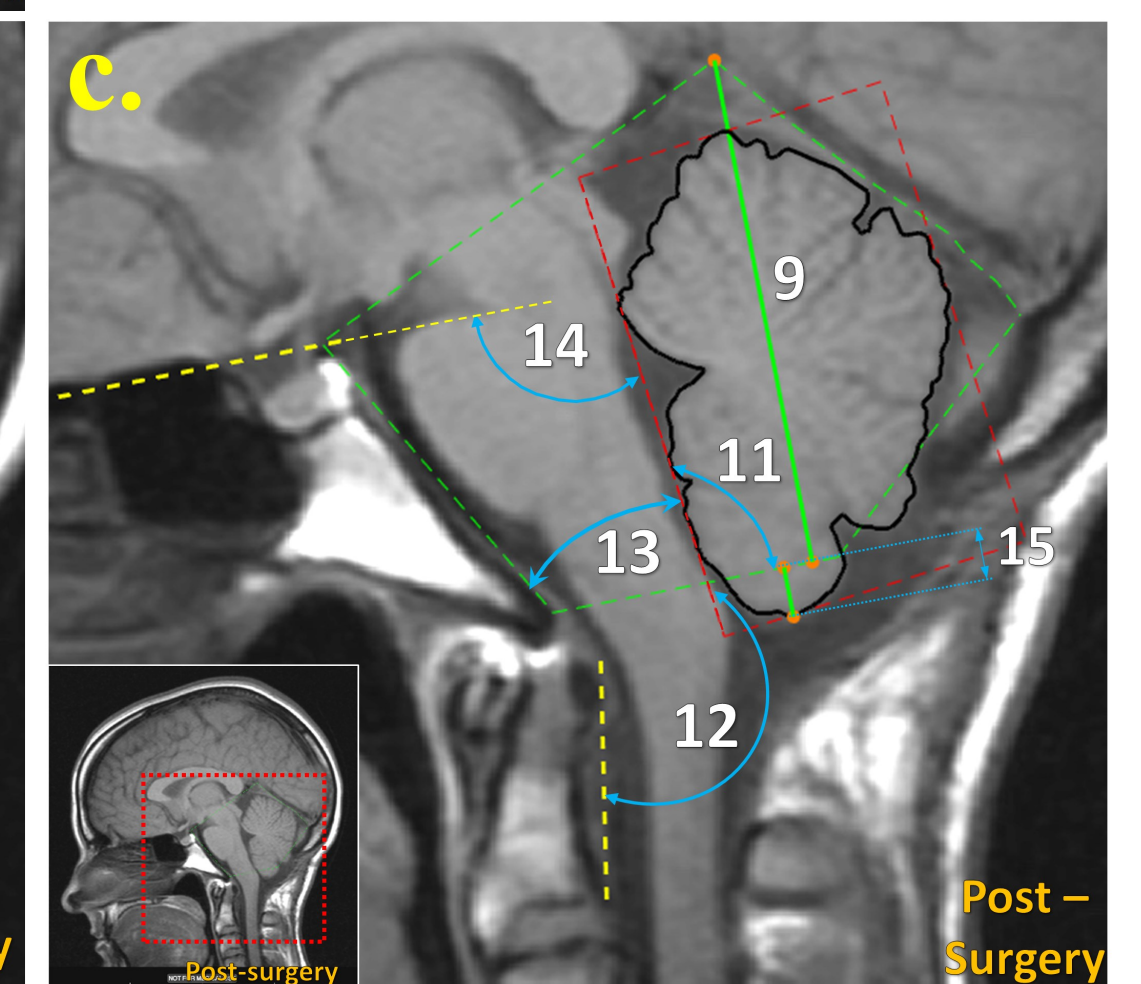
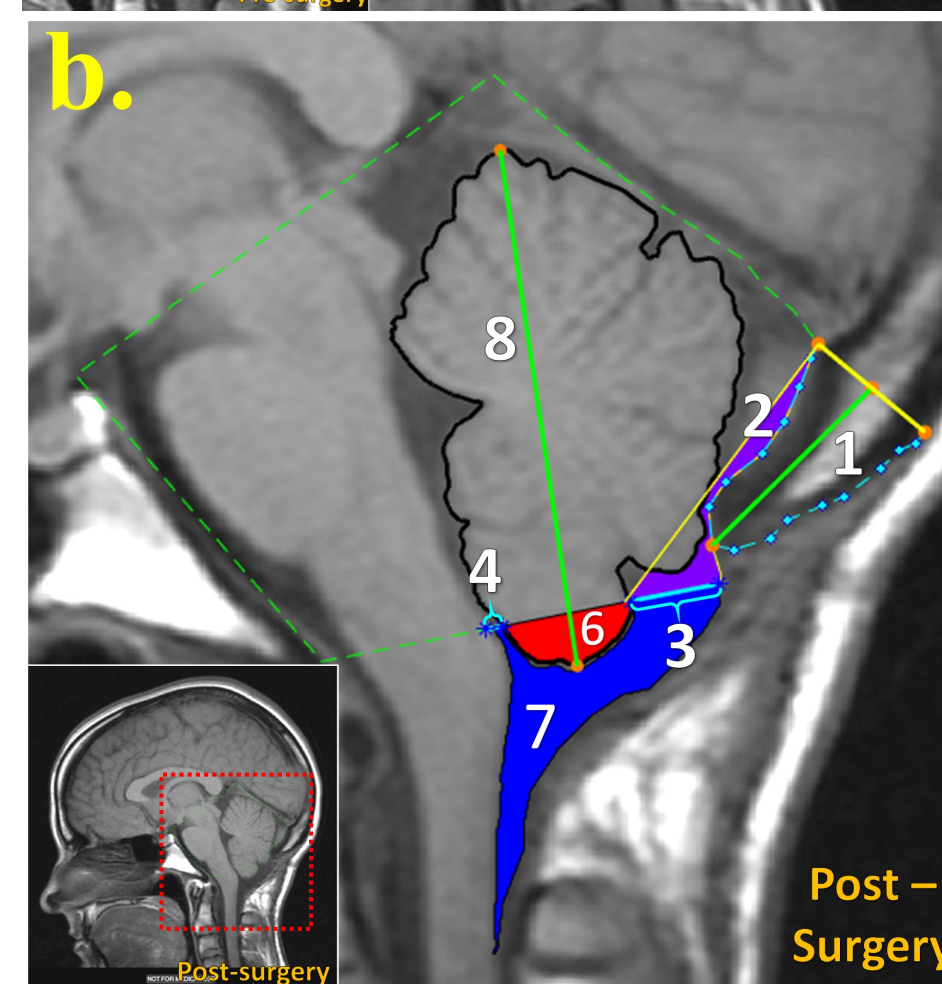
This project demonstrated that it is possible to quantify the morphological changes associated with decompression surgery. Currently, surgeons evaluate the technical success of surgery, meaning the amount of space created, qualitatively. This technique may provide them with valuable data in evaluating patients with residual symptoms. In the future, these measurements can be linked to outcomes in an effort to establish decompression targets for a successful surgery.

Group Differences in CMI morphology before and after surgery

#	Measurements	W/t	p	Before Surgery			After Surgery			Cohen's d
				N	Mean	Stand Dev	N	Mean	Stand Dev	
1	Occipital bone length	21.5	< 0.001	41	41.4	4.89	41	16.9	8.78	3.36
2	CSF area posterior to PCF	6.00	< 0.001	41	21.7	27.9	41	134	98.9	-1.10
3	Posterior dorsal CSF width	6.00	< 0.001	37	0.866	0.718	37	8.66	6.87	-1.15
4	Anterior dorsal CSF width	173	0.007	37	1.48	0.624	37	2.22	1.57	-0.473
5	Total dorsal CSF width	7.00	< 0.001	41	2.34	0.99	41	12.0	8.18	-1.20
6	Tonsil area	3.68	< 0.001	38	80.9	50.1	38	60.3	39.4	0.597
7	Posterior CSF area inferior to McRae	8.00	< 0.001	39	86.3	38.3	39	226	131	-1.10
8	Cerebellum height	5.00	< 0.001	42	64.6	6.05	42	61.7	5.43	0.771
9	PCF height	-0.408	0.685	42	63.4	4.94	42	63.5	5.17	-0.063
10	Cerebellum to PCF height ratio	5.71	< 0.001	42	1.02	0.101	42	0.98	0.096	0.881
11	Cerebellum-McRae angle	-5.28	< 0.001	42	100	7.52	42	102	8.05	-0.815
12	Cerebellum-anterior dural reflection angle	101	< 0.001	41	180	10.5	41	184	9.49	-0.662
13	Cerebellum-clivus angle	4.11	< 0.001	42	26.4	4.41	42	24.3	4.78	0.634
14	Cerebellum-floor of anterior cranial fossa angle	-3.58	< 0.001	42	90.6	7.41	42	92.7	7.79	-0.553
15	Tonsillar position	5.45	< 0.001	42	8.97	5.19	42	6.00	4.60	0.841



(a) Opisthion approximated in T1-weighted post-surgery MR image based on its relative location to the IOP and the McRae line (BOP) angle identified on a pre-surgery image (inset)



(b-c) Novel morphometric parameters of crowding: **1)** occipital bone length, **2)** CSF area posterior to PCF, **3)** posterior dorsal CSF width, **4)** anterior dorsal CSF width, **5)** total dorsal CSF width (#3 + #4), **6)** tonsil area, **7)** posterior CSF area inferior to McRae line, **8)** cerebellum height, **9)** PCF height, **10)** cerebellum to PCF height ratio, **11)** cerebellum-McRae angle, **12)** cerebellum - anterior dural reflection angle, **13)** cerebellum-clivus angle, **14)** cerebellum - floor of anterior cranial fossa angle, **15)** tonsillar position