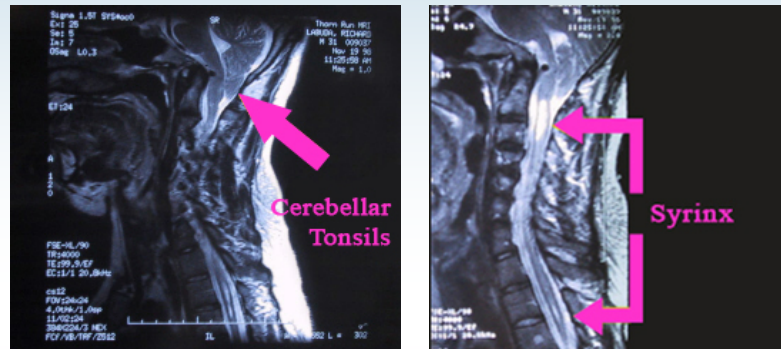


[Frequently Asked Questions](#)[Research Articles](#)[Patient Education Sheets](#)[Book: A Patient's Guide to CM](#)[Tip: Finding a Neurosurgeon](#)[Guide: Leaving the Hospital](#)[Research Conference Videos](#)[MRI](#)[Surgical Scars / Surgery Video](#)[Glossary of Medical Terms](#)

The magnetic resonance imaging process involves **Magnets**, **Resonance** (vibration), and **Imaging** (creating pictures). The MRI is one of the main diagnostic tools in identifying Chiari. Following, are MRI's from the Editor, both before and after surgery, plus excerpts from the Radiologist's original report.

Before Surgery



Excerpted From The Radiologist's Report -

MRI OF THE CERVICAL SPINE WITHOUT CONTRAST

History: Right-sided neck pain; headaches; abnormal X-ray

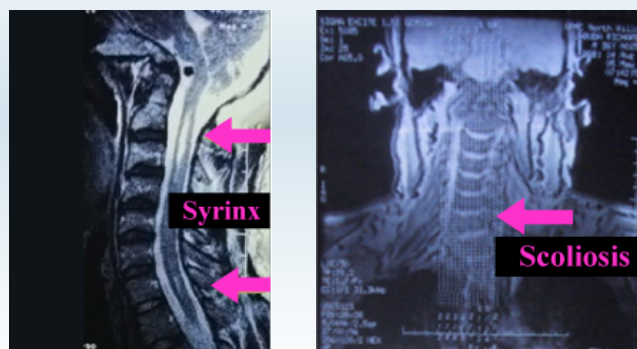
The cervical vertebrae appear normal in stature, alignment, and signal intensity; however, the odontoid process and anterior arch of C1 appear high on the sagittal images, suspicious for basilar impression....

...However, the cerebellar tonsils are ectopic, extending about 1.5 cm below the foramen magnum. In addition, a syrinx is present which most prominent at the C2-C3 level where it has a maximum diameter of about 9 mm. On some of the images, the syrinx is barely perceptible, although there is a re-expansion at the T2-T3 level where it measures about 4 mm in diameter....

IMPRESSIONS:

- The findings are consistent with a Chiari I malformation associated with a syrinx which is most prominent in the upper cervical region, although there is also a prominent area of expansion in the upper thoracic cord.
- The outside radiographs were not available for correlation; basilar impression may be present.
- No disc herniation or spinal stenosis.
- Incidental note was made of the right vertebral artery coursing anterior the the spinomedullary junction at the foramen magnum. This is of questionable clinical significance.

After Surgery (5 yrs. post-op)



NOTES:

- Even years after surgery, the syringes are still present, however they are smaller and no longer are pushing the spinal cord out.
- The cerebellar tonsils are rounder and higher in the skull.
- Scoliosis (abnormal curvature of the spine) is common with syringomyelia, even in adults. The MRI on the right shows scoliosis in the neck and upper back.
- To learn about the diagnostic process of MRI see our [Diagnostic Presentation](#)

Practical Tips for Patients

- It is very difficult to interpret MRI's. We highly recommend you don't try to read your own MRI's and wait until you see the doctor. Speaking from experience, you can cause yourself unnecessary worry and concern. The same rule applies with the radiologist's report. It will be full of medical jargon and trying to decipher it before meeting with the doctor can be difficult.
- However, you can ask your doctor to review the Radiologist's report with you. This way you can find out if your doctor agrees with the Radiologist. Once you have a general idea of the meaning of the report, you can do some research to understand the details.
- Keep a copy of all your MRI's, in case you move or want a second opinion. You will probably not get a copy of the Radiologist's report unless you ask the doctor's office to make you a copy. Alternately, you can call the Imaging Center periodically to get a copy of the reports.
- Many imaging centers are now able to provide copies of the images in electronic format. Find out if this is possible and ask for both hard copies and a disc.
- If possible, try to go to the same Imaging Center for all your MRI's. That way the scans are done on the same equipment, the Radiologist has old scans for comparison, and all your records are in one place.

[Home](#) | [About Us](#) | [Email](#) | [Donate](#) | [Get Involved](#) | [Privacy Policy](#)

Disclaimer: This publication is intended for informational purposes only and may or may not apply to you. The editor and publisher are not doctors and are not engaged in providing medical advice. Always consult a qualified professional for medical care. This publication does not endorse any doctors, procedures, or products.

© 2003-2020 C&S Patient Education Foundation