

Key Points

1. Research has repeatedly shown that the amount of tonsillar herniation is not linked to symptom severity
2. Some experts believe the current definition of Chiari (>3mm-5mm herniation) is not a good definition
3. People with Chiari like symptoms but little or no herniation are sometimes referred to as Chiari 0
4. Research has also consistently shown that Chiari patients have smaller posterior fossas than normal
5. This study used MRI's to take 9 different measurements in the posterior fossa region of 22 Chiari 0 patients and compared them to normal MRI scans
6. Identified 4 different measurements that were significantly different in the Chiari group
7. Authors say definition of Chiari might have to change, but do not yet recommend surgery if there is little to no herniation

Definitions

basiocciput - the base of the occipital bone

basisphenoid - one of the bones in the base of the skull

cerebrum - main portion of the brain comprised of the right and left hemispheres

Chiari 0 - term loosely used to describe people who have Chiari-like symptoms, but have little to no tonsillar herniation

clivus - sloped bone in the base of the skull

hypoplasia - abnormal, underdevelopment; in reference to Chiari, the undersize posterior fossa region

occipital bone - the back/bottom of the skull

Is Chiari 0 For Real? Research Shows Small Posterior Fossa In Chiari

January 20, 2006 -- Defining exactly what Chiari is is not an easy task. Because Hans Chiari first described the condition in terms of the cerebellar tonsils herniating out of the skull, most people define Chiari as tonsillar herniation of greater than 3mm-5mm. Herniation is defined (or measured) as the distance below the foramen magnum, or the opening at the bottom of the skull through which the brain and spine meet.

While this definition is still widely used today (potentially to the harm of many patients), research has continued to show that the amount of tonsillar herniation is not related to severity of symptoms or clinical outcome. In fact, some people have significant herniations, greater than 3mm, with no symptoms. In fact, one study examined over 12,000 MRI's (Elster et al.) and found that over 30% of the people who had herniations greater than 5mm were symptom free.

Conversely, some people exhibit classic Chiari-type symptoms with little to no herniation. Having symptoms with no herniation is sometimes referred to as Chiari 0, and has become a controversial subject. Some surgeons believe that operating on Chiari 0 type patients is beneficial, while others remain skeptical.

Unfortunately, the way Chiari is defined now causes problems for patients in two ways. Some patients, with significant herniations and symptoms, are told that Chiari is no big deal, lots of people have herniations, and that it is benign. At the other end of the spectrum, Chiari 0 patients are told they don't have Chiari because there is only a little herniation, and their symptoms are dismissed as being due to something like stress, or emotional problems.

This limited usefulness of tonsillar herniation in defining Chiari has led many experts to base their diagnoses not solely on MRI's, but rather on a combination of MRI, cine MRI, symptoms, neurological exam, and their own experience and judgment. It has also led researchers to look beyond the herniation measurement for more useful metrics which might define the Chiari condition.

Along those lines, several research studies over the years have focused on the size of the posterior fossa region in Chiari patients. The posterior fossa is the area in the back of the skull, near the bottom where the cerebellum and brain stem are situated. Research has shown that in general, Chiari patients have smaller posterior fossa's than average people. This has led to the theory that Chiari is not a disorder of the brain, but rather a result of the skull being too small for a normal sized brain.

Now, a team from the Allegheny Neuroscience Institute in Pittsburgh, led by Dr. Sekula and Dr. Jannetta, have extended this line of research and shown that so-called Chiari 0 patients tend to have small posterior fossa's, similar to Chiari I patients. They published their work in December, 2005 in the journal Cerebrospinal Fluid Research.

Specifically, they looked at 22 patients who were suffering from Chiari like symptoms (see Table 1) and compared their MRI's to 25 people with no evidence of Chiari or syringomyelia (they had been treated for trigeminal neuralgia). The Chiari 0 group [Ed. note: the authors did not use the term Chiari 0 in their paper, they referred to the group as Chiari-like] was comprised of 15 women and 7 men. On average they had been experiencing symptoms for more than 7 years, and none had been treated surgically.

The patients were given a complete exam, and filled out both a symptom check-list and a personality assessment. The personality assessment was designed to identify anyone with emotional problems or who was depressed. In addition, the group underwent MRI's which were then reviewed by a physician who did not know their diagnosis.

Based upon the results from other studies, the team decided to look at nine different measurements in the posterior fossa region (see image below).

posterior fossa - region in the back, bottom of the skull where the cerebellum and brain stem are situated

tentorium - space between the cerebellum and the cerebrum

cerebellar tonsils - portion of the cerebellum located at the bottom, so named because of their shape

cerebellum - part of the brain located at the bottom of the skull, near the opening to the spinal area; important for muscle control, movement, and balance

cerebrospinal fluid (CSF) - clear liquid in the brain and spinal cord, acts as a shock absorber

Chiari malformation I - condition where the cerebellar tonsils are displaced out of the skull area into the spinal area, causing compression of brain tissue and disruption of CSF flow

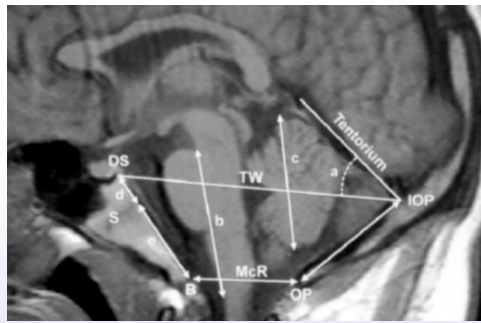
decompression surgery - general term used for any of several surgical techniques employed to create more space around a Chiari malformation and to relieve compression

MRI - magnetic resonance imaging; large device which uses strong magnetic fields to produce images of soft tissue inside the human body

syringomyelia (SM) - neurological condition where a fluid filled cyst forms in the spinal cord

syrinx - fluid filled cyst in the spinal cord

tonsillar herniation - descent of the cerebellar tonsils into the spinal area; often measured in mm



They found that in the Chiari 0 group, 4 of the nine measurements were significantly different from the control group (see Table 2). The clivus, the basiocciput, and the basisphenoid were all smaller in the Chiari group, and the tentorial angle was steeper. Interestingly, the most significant difference between the two groups was the clivus. An article in the December issue of Chiari & Syringomyelia News ([Tracing The Origins Of Chiari](#)) reported on a study which hypothesized that Chiari is due to a problem in the development of this exact structure. It should also be noted that the size of the cerebellum was not significantly different between the two groups.

While the authors believe that their findings indicate that the current definition of Chiari may be too restrictive, they are cautious about the surgical implications until more research is done. At this time, they do not recommend surgery for patients with minimal herniation, but suggest observation instead.

The findings from one study are not likely to eliminate the controversy surrounding Chiari 0, but it is certainly a start.

Table 1
Selected Symptoms of Chiari 0 Group (22 Patients)

Symptom	% of group with
Headache	73
Trouble Swallowing	50
Abnormal Gag Reflex	50
Abnormal Sensations in Legs	55
Dizziness	59

Table 2
Selected Posterior Fossa Measurements of Chiari 0 vs Control Groups

Measure	Chiari 0	Ctrl	Sig?
clivus (d+e)	32.95	43.00	Y
basisphenoid (d)	18.63	23.64	Y
basiocciput (e)	14.00	19.36	Y
hindbrain (b)	47.05	46.40	N
cerebellum (c)	47.36	47.04	N
tentorial angle (a)	41.27	34.84	Y

Note: Distances in mm, angle in degrees, Sig? refers to whether the difference between the groups was statistically significant and not likely due to chance

Related C&S News Articles:

[Tracing The Origins Of Chiari](#)

[Chiari Link To Small Posterior Fossa Confirmed In Adults](#)

[Looking Back: Milhorat Redefines Chiari](#)

[Rickets Provides Chiari Clues](#)

[Between Chiari I & Chiari II](#)

Source

Sekula Jr RF Jr, Jannetta PJ, Casey KF, Marchan EM, Sekula LK, McCrady CS. [Dimensions of the posterior fossa in patients symptomatic for Chiari I malformation but without cerebellar tonsillar descent.](#) Cerebrospinal Fluid Res. 2005 Dec 18;2(1):11

Disclaimer: This publication is intended for informational purposes only and may or may not apply to you. The editor and publisher are not doctors and are not engaged in providing medical advice. Always consult a qualified professional for medical care. This publication does not endorse any doctors, procedures, or products.

© 2003-2020 C&S Patient Education Foundation