

Key Points

1. Complication rates from Chiari surgery are usually less than 5%
2. Most common complications are infection, CSF leak, and pseudomeningocele
3. Cerebellar slumping is a serious complication which can result from the loss of bone supporting the brain
4. Study looked at a surgical technique which rebuilt the posterior fossa box to support the cerebellum in cases of slumping
5. Seven patients underwent the procedure with excellent results
6. Six of the seven had resolution of their symptoms and herniation
7. One patient continued to have headaches, but not as severe

Definitions

brainstem - portion of the brain which connects with the spinal cord; controls many automatic functions such as heart rate, breathing, and swallowing

cerebellar ptosis - also known as cerebellar slumping, serious complication from decompression surgery where the cerebellum sags down and reherniates

craniectomy - surgical procedure where part of the skull is removed

foramen magnum - opening at the base of the skull, through which the spinal cord and brain meet

posterior fossa - area in the back of the skull where the cerebellum is situated

pseudomeningocele - a balloon like extension of the subarachnoid space into the surrounding tissue

cerebellar tonsils - portion of the cerebellum located at the bottom, so named because of their shape

cerebellum - part of the brain

Surgical Technique Alleviates Cerebellar Slumping

May 31, 2007 -- One of the reasons people with Chiari avoid having decompression surgery is because they are afraid of what might go wrong. However, complication rates for Chiari surgery are usually less than 5% and most complications are considered mild (at least by the doctors). The most common complications from decompression surgery include CSF leak, infection and pseudomeningocele.

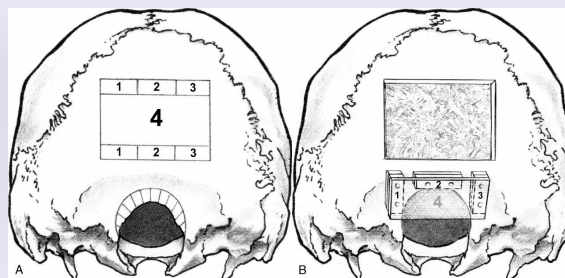
One of the serious complications, whose frequency is not well established, is what is known as cerebellar ptosis or slumping. Decompression surgery involves a craniectomy, meaning that a piece of bone is removed from the back of the skull which covers the cerebellum. In some people, if too much bone is removed, the initial benefits of the additional space that is created gives way to something worse.

Namely, that the brain no longer has the support it needs and essentially slumps down towards the spine. This results in the cerebellar tonsils again herniating and the tissue of the cerebellum can become compressed against the brainstem and the back of the skull. Treating cerebellar ptosis can be difficult because removing even more bone also removes more support and can exacerbate the problem.

Now, a cross-discipline group of surgeons from UCLA (Heller et al.) has developed a surgical technique which appears to alleviate the problems associated with cerebellar slump. They published their technique and their successful results with seven patients in the March, 2007 issue of the Journal of Craniofacial Surgery.

In confronting the problems of cerebellar slumping, the UCLA surgeons wanted to accomplish three things: separate the muscles of the neck from the neural tissue of the brain, prevent the cerebellum from descending, and maintain an expanded (or decompressed) posterior fossa region. To accomplish this, they developed a procedure which involves removing slices of bone from above the initial craniectomy site (see Figure 1A).

Figure 1



It is important to note that the surgeons don't cut completely through the bone, but rather split the thickness of the bone to remove what they need. Next, the pieces marked 1-3 in the figure are used to create legs around the initial craniectomy site (Figure 1B). Then, the larger piece of bone (4) is layed over the legs to create an expanded posterior fossa which is still enclosed and effectively reduces the size of the foramen magnum.

The surgeons used this technique on seven patients they saw between 1994-2004. The patients had all had decompression surgery at other institutions, were suffering from symptoms, and had demonstrable cerebellar slump on MRI. After the posterior fossa box surgery, six of the seven patients experienced a complete resolution of their symptoms (see Table 1). In addition, the cerebellar tonsils for all six returned to their normal position and took on a healthy, rounded shape. One patient still had mild herniation after the surgery and continued to experience headaches, but they were not as severe as before.

The issue of ptosis creates a challenge for neurosurgeons in determining how large of a decompression to perform. Removing too little bone can result in creating not enough space to relieve symptoms, while removing too much can lead to cerebellar slumping. At least now there appears to be an effective technique to treat cerebellar slumping when it does occur.

Table 1
Outcomes After Posterior Fossa Box Expansion

#	PostOp Syrinx	PostOp Tonsils	PostOp Symptoms
1	Collapsed	Normal	Resolved
2	N/A	Mild Herniation	Headache
3	Collapsed	Normal	Resolved

located at the bottom of the skull, near the opening to the spinal area; important for muscle control, movement, and balance

cerebrospinal fluid (CSF) - clear liquid in the brain and spinal cord, acts as a shock absorber

Chiari malformation I - condition where the cerebellar tonsils are displaced out of the skull area into the spinal area, causing compression of brain tissue and disruption of CSF flow

Source

Heller JB, Lazareff J, Gabbay JS, Lam S, Kawamoto HK, Bradley JP. [Posterior cranial fossa box expansion leads to resolution of symptomatic cerebellar ptosis following Chiari I malformation repair.](#) J Craniofac Surg. 2007 Mar;18(2):274-80.

4	Collapsed	Normal	Resolved
5	Collapsed	Normal	Resolved
6	N/A	Normal	Resolved
7	Collapsed	Normal	Resolved

Notes: Normal tonsils refers to no herniation and rounded appearance; Patient 2's symptoms resolved after 8 months

Related C&S News Articles:

[Study Compares Surgical Techniques](#)

[Surgical Technique Reduces Hospital Time And Costs](#)

[To Open or Not To Open The Dura: That Is The Question](#)

[Home](#) | [About Us](#) | [Email](#) | [Donate](#) | [Get Involved](#) | [Privacy Policy](#)

Disclaimer: This publication is intended for informational purposes only and may or may not apply to you. The editor and publisher are not doctors and are not engaged in providing medical advice. Always consult a qualified professional for medical care. This publication does not endorse any doctors, procedures, or products.

© 2003-2020 C&S Patient Education Foundation