

**Key Points**

1. Outcomes studies are common in Chiari literature; however they are becoming more useful as surgeons report more detailed and rigorous information
2. This study reports the outcome of 49 children with Chiari and syringomyelia
3. Authors tracked the time course of both clinical improvement and radiographic improvement, plus specifically looked at syrinx related symptoms
4. Most common SM related symptoms were parasthesia, dysesthesia, weakness, and scoliosis
5. By 14 months after surgery, 55% showed a reduced syrinx on MRI
6. In contrast, 54% showed improvement in symptoms just 4 months after surgery
7. Indicates that MRIs are not a good measure of symptom improvement
8. Motor related symptoms were more likely to improve than numbness and tingling

**Definitions**

- asymptomatic** - having no symptoms
- cervical** - the upper part of the spine, neck region
- craniectomy** - surgical procedure where part of the skull is removed
- dura** - the outer covering of the brain and spinal cord
- duraplasty** - surgical procedure where the dura is cut open and expanded with a patch
- dysesthesia** - an unpleasant, abnormal sensation
- gait** - how someone walks
- laminectomy** - surgical procedure where parts of one or more

**Tracking Syrinx Improvement After Surgery**

November 30, 2008 -- Outcome studies, where a surgeon reports on how a series of patients did after surgery, are common in the Chiari literature. Although they tend to suffer from scientific limitations (such as lack of specific outcome measures) which make them difficult to draw conclusions from, over time the types of data that is reported in these studies has improved and they do provide an interesting snapshot into what patients facing surgery might expect.

A group from Johns Hopkins (Attanello et al.) recently published just such an outcome study in the June, 2008 issue of the journal, Neurosurgery. In it, they reported the surgical results of 49 children with Chiari and syringomyelia, paying particular attention to the syrinx related symptoms. The researchers used imaging, operative records, and clinical records to create a database containing demographic information, symptoms, neurological deficits, imaging characteristics, and surgical records. The syrinx specific symptoms included:

- Parasthesia
- Dysesthesia
- Weakness
- Incontinence
- Gait Instability
- Scoliosis

Naturally, all the children received pre-operative MRIs. They also received an MRI 3 months after surgery, and an additional one 12-18 months after surgery. They were followed for an average of 41 months. For purposes of analysis, a reduction in size of a syrinx on MRI by 20% or more was considered a decrease. Anything less than 20% was considered to be no change.

The average age of the children at the time of surgery was 11 years. Although they all had syrinxes, 20% were found to have no symptoms directly associated with syringomyelia (they did of course have Chiari related symptoms bad enough to warrant surgery). Nearly half the children suffered from numbness and tingling (parasthesia), and more than a quarter from painful sensations (dysesthesia, Figure 1). In addition, 41% had some degree of scoliosis. Ninety-four percent of the children had a syrinx involving the cervical region, and in about half the thoracic region was affected. The average syrinx size was more than six vertebral segments, and in six children the syrinx ran the length of the cord.

Clinically, 54% of the children experienced an improvement of their symptoms 4 months after surgery (Figure 3). This had increased to 61% by one year. Only one child experienced an improvement after the one year mark. In looking at specific symptoms, the researchers found that motor related symptoms were more likely to improve than the numbness/tingling (Figure 2).

Interestingly, improvement on MRIs came much later than the reported symptom improvement. Specifically, 55% of the cases showed a decrease in the syrinx, but it took 14 months after surgery for this to occur. Within this group, 6 children had their syrinx resolve completely and 21 had it decrease in size. One child's syrinx actually grew in size and that child underwent a reoperation. The 55% reduction rate is lower than some other published literature, but the authors point out that if they changed their criteria to any reduction in size (as opposed to at least 20%), then the number jumps to 73%, which is in line with other reports. The authors also point out that the children with persistent symptoms were very likely to have progressive scoliosis, even after decompression surgery.

It is difficult to say what can be drawn from this study, but it is interesting to compare yourself (or your child) to a group. Perhaps the strongest statement that can be made is that it is very apparent that defining "success" by a reduction in the size of syrinx on MRI, is not necessarily linked to success from a symptom point of view.

**Figure 1: Prevalence of Syrinx Specific Symptoms (49 Patients)**

| Symptom      | % With |
|--------------|--------|
| Asymptomatic | 20%    |
| Parasthesia  | 49%    |
| Dysesthesia  | 28%    |

vertebra are removed

**MRI (magnetic resonance imaging)** - device which uses strong magnets to create a detailed image of inside the body; for Chiari the brain and spine

**parasthesia** - numbness, tingling

**scoliosis** - abnormal curvature of the spine

**thoracic** - the middle part of the spine, chest area

**vertebra** - one of the bony segments of the spine

**cerebellar tonsils** - portion of the cerebellum located at the bottom, so named because of their shape

**cerebrospinal fluid (CSF)** - clear liquid in the brain and spinal cord, acts as a shock absorber

**Chiari malformation I** - condition where the cerebellar tonsils are displaced out of the skull area into the spinal area, causing compression of brain tissue and disruption of CSF flow

**syringomyelia** - condition where a fluid filled cyst forms in the spinal cord

### Source

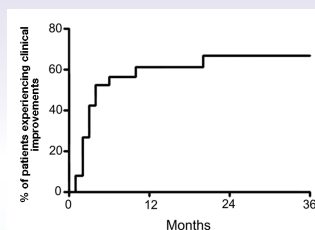
Attenello FJ, McGirt MJ, Gathinji M, Dato G, Atiba A, Weingart J, Carson B, Jallo GI. [Outcome of Chiari-associated syringomyelia after hindbrain decompression in children: analysis of 49 consecutive cases](#). Neurosurgery. 2008 Jun;62(6):1307-13

|                  |     |
|------------------|-----|
| Weakness         | 21% |
| Incontinence     | 15% |
| Gait Instability | 8%  |
| Scoliosis        | 41% |

**Figure 2: Improvement By Symptom**

| Symptom          | % Improved |
|------------------|------------|
| Parasthesia      | 42%        |
| Dysesthesia      | 73%        |
| Weakness         | 75%        |
| Incontinence     | 50%        |
| Gait Instability | 100%       |
| Scoliosis        | 47%        |

**Figure 3: Time Course of Symptom Improvement**



**Note: Y axis = percent of patients with improved symptoms; X axis = time in months after surgery**

### Related C&S News Articles:

[Fluid Motion Inside Syrinx Predicts Post-op Shrinkage](#)

[Study Shows Most Syrinxes Shrink Significantly Three Months After Surgery](#)

[Large Study Finds 80% Improve With Surgery](#)

[Surgery Improves Quality Of Life For About 80% Of Patients](#)

[Large Study Examines Surgical Outcomes In Children](#)

[Home](#) | [About Us](#) | [Email](#) | [Donate](#) | [Get Involved](#) | [Privacy Policy](#)

**Disclaimer:** This publication is intended for informational purposes only and may or may not apply to you. The editor and publisher are not doctors and are not engaged in providing medical advice. Always consult a qualified professional for medical care. This publication does not endorse any doctors, procedures, or products.

© 2003-2020 C&S Patient Education Foundation