

### Key Points

1. Morphometric research involves using MRIs to take quantitative measurements of the skull
2. In general this type of research has shown that Chiari patients tend to have abnormal posterior fossas
3. However, measures of total volume have produced inconsistent results
4. French study looked at 17 adult Chiari patients compared to a group of controls
5. Found that only the length of the basiocciput bone was significantly different
6. The brains of the Chiari patients were similar in size to those of the controls
7. Researchers point out that it is not clear why if the bone undergrowth occurs at the embryo stage that symptoms develop over such a wide range of ages

### Definitions

**brainstem** - base of the brain which connects to the spinal cord and controls basic functions such as breathing and heart rate

**foramen magnum** - opening in the base of the skull through which the brain and spine connect

**hypoplasia** - underdevelopment of a body part

**morphometric** - in this article, refers to measuring dimensions of the skull and brain

**posterior fossa** - region in the back of the skull where the cerebellum is situated

**skull base** - the lower bones of the skull

**cerebellar tonsils** - portion of the cerebellum located at the bottom, so named because of their shape

**cerebellum** - part of the brain located at the bottom of the skull,

## Chiari Again Linked To Lack Of Skull Growth

July 31, 2009 -- For several years now, researchers have been using MRIs to measure skull base dimensions of Chiari patients in what is known as morphometrics. It was from this type of research that emerged the theory that a significant number of Chiari cases - if not a majority - are caused by an underdevelopment of the skull in the occipital area (Figure 1). In other words, it is not that the brain is too big for the skull, but rather that the skull is too small for the brain.

While the evidence is fairly strong that there is something of interest in the posterior fossa region of Chiari patients, as is often the case, the devil is in the details. Researchers have used various methods to measure the posterior fossa volume and in some cases have found that indeed on average Chiari patients tend to have smaller posterior fossas than normal. However, this is not true for every patient and other studies have contradicted this finding, with one showing that only Chiari men had smaller posterior fossas, and another finding that only patients with both Chiari and syringomyelia had smaller posterior fossa regions. Because of this, researchers are still exploring different ways to analyze the relative size of this skull region. Some have tried using a volume ratio of skull to brain tissue, while others have turned to measuring specific bone segments as opposed to general volume measurements.

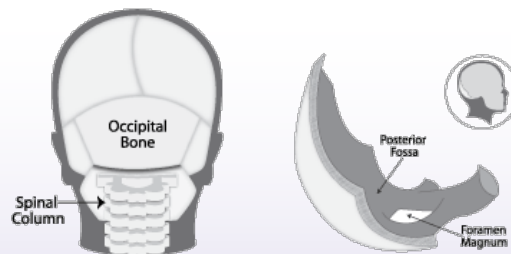


Figure 1: Occipital Bone and Posterior Fossa (from Conquer Chiari: A Patient's Guide)

This is the approach that a group of French researchers took in using morphometrics to look for skull undergrowth in a group of 17 adult Chiari patients as compared to a group of healthy controls. They published their findings recently on-line in the Journal of Neurosurgery. All the Chiari patients had at least 5mm of herniation and were clearly symptomatic. The controls were taken from people who had had MRIs associated with migraines but were found to not have any herniation. Based on previously published morphometric studies, the researchers decided to focus on 4 skull measurements and 3 brain tissue measurements (Figure 2 and Figure 3).

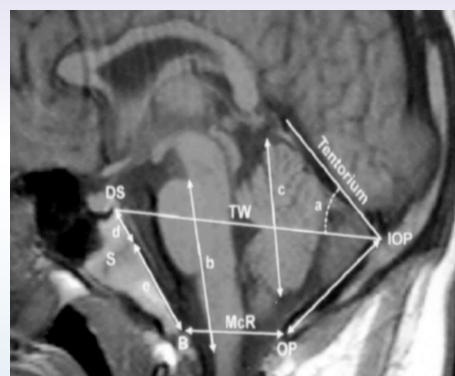


Figure 2: Skull Measurements Used in Study:

- a) basiocciput, FM) foramen magnum (FM), b) supraocciput, c) tentorial angle

near the opening to the spinal area; important for muscle control, movement, and balance

**cerebrospinal fluid (CSF)** - clear liquid in the brain and spinal cord, acts as a shock absorber

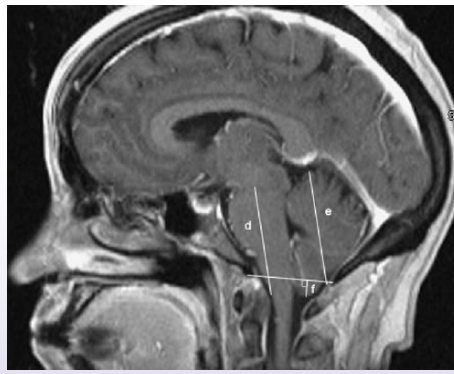
**Chiari malformation I** - condition where the cerebellar tonsils are displaced out of the skull area into the spinal area, causing compression of brain tissue and disruption of CSF flow

**decompression surgery** - general term used for any of several surgical techniques employed to create more space around a Chiari malformation and to relieve compression

**syringomyelia** - condition where a fluid filled cyst forms in the spinal cord

### Source

[Incidence of basioccipital hypoplasia in Chiari malformation Type I: comparative morphometric study of the posterior cranial fossa.](#) Noudel R, Jovenin N, Eap C, Scherpereel B, Pierot L, Rousseaux P. J Neurosurg. 2009 May 22. [Epub ahead of print]



**Figure 3: Brain Measurements Used in Study:**

d) hindbrain length, e) cerebellum length, f) tonsillar herniation

The researchers found that of the four skull measurements, only the basiocciput differed significantly between Chiari patients and the controls (Table 1). Specifically, for the Chiari group the average length of this bone was 19.4 mm compared to 25.7 mm for the controls. Interestingly, the brainstem and cerebellum lengths didn't differ between the two groups, supporting the idea that the brains of Chiari patients are of normal size. Also of note was that the fact that the length of tonsillar herniation did not correlate to any other measurements, providing even more evidence that the size of a Chiari malformation is not a good indicator of the crowding or symptoms.

In discussing their findings, and the entire idea of a small posterior fossa, the authors make an interesting point; namely that if the skull abnormalities found with Chiari are due to a defect in the early embryo, why is there such a range in the age when symptoms become apparent? Why isn't everyone symptomatic at a very early age? One possibility, as the authors note, is that there are actually different mechanisms which can lead to a mismatch between the skull and the brain. For example, some skull sutures don't fully close until late teens or adulthood, which could push back symptoms. This would imply that in some cases Chiari is actually a dynamic phenomenon, and there are case studies which support this view.

However, another possibility is that crowding alone doesn't always lead to symptoms. For example, perhaps over time scar tissue and adhesions build up which then lead to symptoms. Of course a wild card in all of this speculation is what role physical trauma plays in sparking symptoms, which is currently not well understood.

Morphometrics is a promising area of Chiari research, but in order to really have an impact results from these types of studies must be synthesized into some type of useful theory.

**Table 1: Morphometric Measurements, Chiari vs Controls**

	Chiari	Control	Sig?
basiocciput (mm)	19.4	25.7	Y
foramen magnum (mm)	37.1	35.4	N
supraocciput (mm)	40.7	40.9	N
tentorial angle (degrees)	85.3	84.6	N
brainstem (mm)	40.7	43.2	N
cerebellum (mm)	52.7	49	N

**Note:** Sig? refers to whether the difference between groups was statistically significant and not likely due to chance.

### Related C&S News Articles:

[Can A Child Grow Out Of Chiari?](#)

[More Findings Involving Chiari & Abnormal Skull Geometry](#)

[Can Posterior Fossa Volume Indicate Symptom Severity?](#)

[Small Posterior Fossa Linked To Chiari Related Syringomyelia](#)

[Is Chiari 0 For Real? Research Shows Small Posterior Fossa In Chiari 0 Patients](#)

[Chiari Link To Small Posterior Fossa Confirmed In Adults](#)

**Disclaimer:** This publication is intended for informational purposes only and may or may not apply to you. The editor and publisher are not doctors and are not engaged in providing medical advice. Always consult a qualified professional for medical care. This publication does not endorse any doctors, procedures, or products.

© 2003-2020 C&S Patient Education Foundation