

Key Points

1. Several studies have found that on average people with Chiari have small posterior fossas
2. This has led some to describe Chiari as a developmental problem where the skull is too small for the brain
3. Research has also identified a genetic component to Chiari
4. This study looked at the posterior fossa volumes of a multi-generational family affected by Chiari
5. Family members all had normal sized posterior fossas as compared to age matched controls
6. Clearly a different mechanism is responsible for Chiari in these cases
7. There are currently several possible underlying causes of Chiari which require further investigation

Definitions

control group - in a research study, a group of people who are similar to the subjects under study in age and gender but are assumed to be healthy; the control group serves as a basis for comparison

fossa - a depression

posterior - towards the back

posterior fossa - area of the back of the skull where the cerebellum is situated

pseudotumor cerebri - condition where the pressure of CSF in the brain is chronically elevated

skull base - the lower bones of the skull

shunt - a tube like device which is surgically implanted in order to drain or redirect CSF.

cerebellar tonsils - portion of the cerebellum located at the bottom, so named because of their shape

Multi-Generational Chiari Family Adds To Confusion

January 31, 2008 -- The underlying causes of Chiari malformation are not completely understood, and a recent study involving a multi-generational Chiari family may have confused the picture even more. Some cases of Chiari are easy to understand, for example a mass in the brain - such as a tumor or cyst - can push the cerebellum out resulting in Chiari. However, in many cases the underlying cause is not as clear.

Several theories have been put forth over the years which may explain Chiari in different subsets of patients (Figure 1). Some people believe that Chiari may be due to tethering of the spinal cord which results in downward traction. Other Chiari cases seem to be linked to altered CSF dynamics, such as with pseudotumor cerebri. The role of trauma in Chiari, such as with car accidents, is not well understood but with so many patients reporting trauma as a triggering event, it must be taken into account by any comprehensive theory. In addition, it appears there is a genetic component to Chiari. There is now sufficient evidence to suggest that some percentage of Chiari cases have a genetic basis. To date, no Chiari gene has been identified, but scientists have identified specific chromosomes where such genes may be located.

One leading theory on the underlying cause of Chiari involves the posterior fossa region of the skull, which is the depression in the back where the cerebellum is situated. Research has revealed that on average Chiari patients tend to have small posterior fossas, which has led some doctors and scientists to describe Chiari as a developmental problem which results in a skull which is too small for the brain. In studying this theory, researchers have developed methods to measure the volume of the posterior fossa from MRI images and have found specific anatomical features in the base of the skull which tend to be abnormal in Chiari patients.

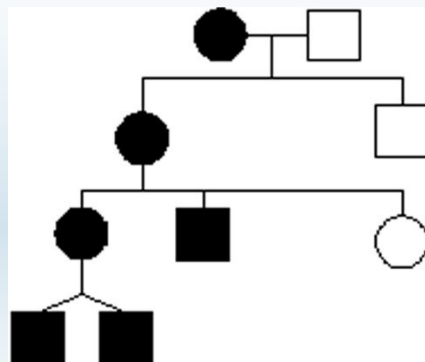
Because it arises from embryological development, the small posterior fossa theory lends itself to having a genetic component. However, a study of a family with four generations of Chiari patients published in the January, 2008 issue of the *Journal of Neurosurgery: Pediatrics* (Tubbs et al.), shows that with Chiari, nothing is simple. Specifically, Tubbs used MRI images to measure the posterior fossa volume of 5 out of 6 affected family members, and compared the results to age-matched normal controls.

The family included (Figure 2):

- Case 1: A woman who was found to have Chiari upon autopsy and who had no known symptoms
- Case 2: Her daughter who developed dizziness and neck pain at the age of 56
- Case 3: The son of Case 2, who developed back and neck pain at 40
- Case 4: The daughter of Case 2, who developed headaches at 37
- Cases 5 & 6: The twin sons of Case 4, who developed headaches and neck pain at 16.

All the family members (except Case 1) were found to have Chiari with herniations ranging from 6-25mm, and one of the twin boys also had a syrinx. None of the affected family members had a history of head trauma or other genetic conditions which could explain the presence of symptomatic Chiari. Cases 2, 4, 5, and 6 underwent decompression surgery which resolved their symptoms.

Figure 2: Generational Family Members Affected By Chiari



Note: Black squares/circles are family members with Chiari. Squares represent males; circles represent females.

The researchers used a well established method to measure the posterior fossa volume from the MRIs of Cases 2-6. When they compared the measured volumes to age-matched controls from other research

cerebellum - part of the brain located at the bottom of the skull, near the opening to the spinal area; important for muscle control, movement, and balance

cerebrospinal fluid (CSF) - clear liquid in the brain and spinal cord, acts as a shock absorber

Chiari malformation I - condition where the cerebellar tonsils are displaced out of the skull area into the spinal area, causing compression of brain tissue and disruption of CSF flow

decompression surgery - general term used for any of several surgical techniques employed to create more space around a Chiari malformation and to relieve compression

Source

Tubbs RS, Hill M, Loukas M, Shoja MM, Oakes WJ. [Volumetric analysis of the posterior cranial fossa in a family with four generations of the Chiari Malformation Type 1](#). J Neurosurg Ped. 2008 Jan (1 Suppl): 21-24.

publications, they found no significant differences. In other words, all the family members had normal sized posterior fossas.

This is not the first study to question the scope of the posterior fossa theory. Sgouros found that children with Chiari only had normal sized posterior fossas, but children with Chiari and syringomyelia had small posterior fossas. The published research which has linked small posterior fossas to Chiari tends to average the Chiari patients together, which can hide the fact that some patients have small posterior fossas, but others may not.

Although only focused on one family, this study strongly suggests that even in cases that likely have a genetic component, a small posterior fossa may not be the problem. As researchers continue to look for the underlying causes of Chiari, they will need to move beyond grouping all Chiari cases together and develop ways to separate and classify them.

Figure 1 **Possible Causes of Chiari Malformation**

- Small posterior fossa
- Hydrocephalus
- Mass in skull (tumor)
- CSF disorder (pseudo-tumor cerebri)
- Tethered cord
- Over shunting
- Trauma
- Genetic component

Note: The above represents a list of possibilities only. More research is required to further identify and validate the underlying cause(s) of Chiari.

Related C&S News Articles:

[More Findings Involving Chiari & Abnormal Skull Geometry](#)

[Small Posterior Fossa Linked To Chiari Related Syringomyelia](#)

[Children With Chiari Symptoms Due To Shunting Found To Have Small Posterior Fossa Volume](#)

[Is Chiari 0 For Real? Research Shows Small Posterior Fossa In Chiari 0 Patients](#)

[Chiari Link To Small Posterior Fossa Confirmed In Adults](#)

[Home](#) | [About Us](#) | [Email](#) | [Donate](#) | [Get Involved](#) | [Privacy Policy](#)

Disclaimer: This publication is intended for informational purposes only and may or may not apply to you. The editor and publisher are not doctors and are not engaged in providing medical advice. Always consult a qualified professional for medical care. This publication does not endorse any doctors, procedures, or products.

© 2003-2020 C&S Patient Education Foundation