

Key Points

1. Syringomyelia can be caused by a Chiari malformation, trauma, tumors, and infection
2. Surgery for syringomyelia not related to Chiari can involve a local decompression of the spine or directly shunting the syrinx
3. Success rates for syringomyelia surgery are only about 60-70%
4. Doctors used SPAMM MRI on 14 patients to see if the motion of fluid inside a syrinx could predict syrinx reduction after surgery
5. In general, good fluid motion inside the syrinx pre-op was correlated with a reduction in syrinx size post-op
6. Interestingly, all the Chiari related SM patients had good intrasyrinx fluid motion
7. Researchers believe this type of fluid motion indicates that the CSF is still responding to the cardiac cycle which allows for the syrinx to drain

Definitions

decompression - surgical technique where more space is created around something, such as the cerebellar tonsils or a syrinx

MRI - magnetic resonance imaging; technique which uses magnets to visualize internal body parts

phase contrast MRI - MRI technique which can show the flow and speed of CSF

shunt - tube like surgical device which is used to drain or redirect fluid

SPAMM - spatial modulation of magnetization; MRI technique which allows for the measurement of movement, such as CSF velocity

spinal cord - column of nerve tissue which runs down from the brain through the bony spine

Fluid Motion Inside Syrinx Predicts Post-op Shrinkage

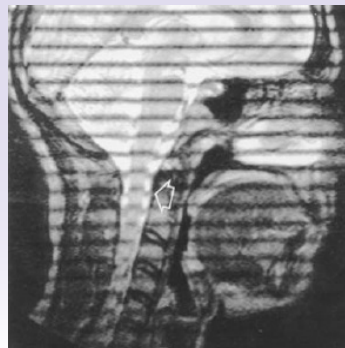
March 31, 2008 -- Researchers from Korea have shown that measuring the motion inside of a syrinx prior to surgery can predict whether the syrinx will shrink in size after surgery. Their finding was based on a study involving 14 syringomyelia patients and was published in the January, 2008 issue of the Journal of Computer Assisted Tomography.

Although syringomyelia (SM) is most commonly caused by a Chiari Malformation, it can also be caused by trauma, tumors, and infection. There are several theories involving how syrinxes develop and grow, with some focused on abnormal CSF flow which results in CSF being trapped inside the cord and collecting into a cyst. Other theories focus on mechanical forces on the cord which result in extracellular fluid becoming trapped and forming a cyst.

Chiari related SM is of course treated by creating more space around the malformation with decompression surgery in an attempt to restore the normal flow of CSF. Other types of SM are treated with local decompressions which attempt to restore the flow of CSF at the level of the syrinx, or by shunting the syrinx directly. Unfortunately, success rates for SM surgery are only about 60-70% and often a good result is when the syrinx stops expanding.

The Korean team decided to use a specific MRI technique known as SPAMM (spatial modulation of magnetization) to carefully study to motion of fluid both inside and outside of the syrinx. The SPAMM technique manipulates the magnetic signals to essentially create black stripes across a standard MRI image (see Figure 1). Any displacement of one of the stripes represents movement of the tissue - or in this case fluid - beneath the stripe. The velocity of that movement is calculated by measuring the displacement of the stripe and dividing that distance by the time it took to acquire that image. Some imaging experts believe that SPAMM is more accurate than phase-contrast MRI because the phase-contrast technique is inherently noisy, which can introduce errors in measurement.

Figure 1: SPAMM Image



Note: Image from Sakas et al, 2005

For this study, the researchers looked at 14 adult syringomyelia patients who had received surgery between 1995-2004. Seven of the patients had Chiari related syringomyelia, while four had a syrinx due to trauma, and three were from infection. Each patient underwent a pre-operative SPAMM MRI to examine both the intrasyrinx fluid flow and the flow of CSF in the subarachnoid space.

From the images, three separate radiologists classified both the syrinx fluid flow and general CSF flow as either good, meaning it moved a minimum amount in cycle with the heartbeat, or poor, meaning there was little movement. In addition, the radiologists measure the width of the syrinx at its widest point.

All patients underwent surgery (however, not the same technique) and were scanned with regular MRI post-operatively. The same radiologists then re-measured the syrinx size. A reduction in the width of the syrinx by 20% or more was considered a good outcome, while less than 20% was considered a poor outcome.

Using this criteria, nine of the patients were classified as having good intrasyrinx motion before surgery. Interestingly, all seven Chiari related SM patients were in this group. Out of the nine with good fluid motion inside the syrinx, eight had good outcomes after surgery (Figure 2). In addition, all five of the patients with poor syrinx motion prior to surgery had poor surgical outcomes, meaning their syrinxes did not come down in size. In total, the status of the fluid motion inside the syrinx was able to predict the surgical outcome 88% of the time.

In looking at general CSF flow, again 9 patients were classified as having good flow, and 5 were classified as

syringomyelia - neurological condition where a syrinx forms in the spinal cord, causing pain, weakness, and sometimes paralysis

syrinx - a fluid filled cavity, or cyst, in the spinal cord

cerebellar tonsils - portion of the cerebellum located at the bottom, so named because of their shape

cerebrospinal fluid (CSF) - clear liquid in the brain and spinal cord, acts as a shock absorber

Chiari malformation I - condition where the cerebellar tonsils are displaced out of the skull area into the spinal area, causing compression of brain tissue and disruption of CSF flow

decompression surgery - general term used for any of several surgical techniques employed to create more space around a Chiari malformation and to relieve compression

Source

Park CH, Chung TS, Kim DJ, Suh SH, Chung WS, Cho YE. [Evaluation of intrasyrinx fluid motion by spatial modulation of magnetization-magnetic resonance imaging in syringomyelia with long-term follow-up: a predictor of postoperative prognosis?](#) J Comput Assist Tomogr. 2008 Jan-Feb;32(1):135-40

having poor flow. Of the 9 with good CSF flow, 8 had a good surgical outcome. Of the 5 with poor flow, 4 had a poor surgical outcome. This resulted in CSF flow agreeing with the surgical outcome 77% of the time.

Interestingly, the combination of intrasyrinx fluid motion and CSF flow agreed 100% with the surgical outcome. In other words, there were 7 patients with both good syrinx motion and CSF flow, and all seven had a good surgical result. In addition, there were 3 patients with both poor syrinx motion and CSF flow, and all three of these patients had a poor surgical outcome.

In discussing their results, the authors believe that motion of fluid within the syrinx indicates that the syrinx is still coupled with the natural flow of CSF in response to the heartbeat. If there is no motion within the syrinx, it can indicate that adhesions and scarring have isolated the syrinx from the CSF system, which makes it difficult for the syrinx to shrink.

SPAMM MRI is certainly an interesting tool for researching syringes, but these results should be treated with caution. The mechanics of syrinx formation and progression are complicated and not well understood, which makes interpreting the significance of motion within a syrinx cavity difficult. However, this study represents an encouraging step in advancing our understanding and may present clinicians with an added piece of data prior to surgery.

Figure 2
Intrasyrinx Fluid Motion & Post-operative Results (14 Patients)

Intrasyrinx Motion	Good Post-op Result	Poor Post-op Result
Good (9)	8	1
Poor (5)	0	5

Figure 3
CSF Motion & Post-op Result

CSF Motion	Good Post-op Result	Poor Post-op Result
Good (9)	7	2
Poor (5)	1	4

Note: Both intrasyrinx fluid flow and CSF flow were good predictors of syrinx shrinkage post-operatively

Related C&S News Articles:

[Total CSF Flow May Predict Surgical Outcome](#)

[CSF Flow Used To Evaluate Surgical Success](#)

[Using Cine-MRI To Predict Surgical Outcome](#)

[CSF Flow In Children Before & After Surgery](#)

[Home](#) | [About Us](#) | [Email](#) | [Donate](#) | [Get Involved](#) | [Privacy Policy](#)

Disclaimer: This publication is intended for informational purposes only and may or may not apply to you. The editor and publisher are not doctors and are not engaged in providing medical advice. Always consult a qualified professional for medical care. This publication does not endorse any doctors, procedures, or products.

© 2003-2020 C&S Patient Education Foundation