

Key Points

1. There have been indications that Chiari can limit the range of motion of the neck in patients
2. Study measured the cervical ROM for 30 adult CWSM patients both before and after surgery
3. Found no significant difference between the pre and post op ROM
4. ROM also was not correlated with either amount of tonsillar herniation or type of syrinx
5. ROM can be tough to measure so it is hard to say if these results really mean Chiari patients have a normal range of motion
6. Also important to note that no patients underwent any type of neck stabilization surgery which can reduce ROM

Definitions

cervical - upper part of the spine, the neck area

dura - thick, outer covering of the brain

extension - bending the neck back

flexion - bending the neck forward

herniation - with Chiari, refers to the cerebellar tonsils extending out of the skull and into the spinal area

laminectomy - surgical procedure where part of one or more vertebra are removed

occiput - bone in the back of the head

ROM - Range of Motion; the range in degrees through which a joint can move

vertebra - one of the bony segments of the spine, referred to by region and number; for example C1 is the first cervical vertebra

cerebellar tonsils - portion of the cerebellum located at the bottom,

Surgery Has No Effect On Cervical Range Of Motion

January 31, 2008 -- A Japanese study has found that decompression surgery has no effect on the cervical range of motion of Chiari patients. The study, published in the November, 2007 issue of the *Journal of Neurosurgery: Spine*, used x-rays to measure the cervical range of motion (ROM) of 30 adult Chiari and syringomyelia patients.

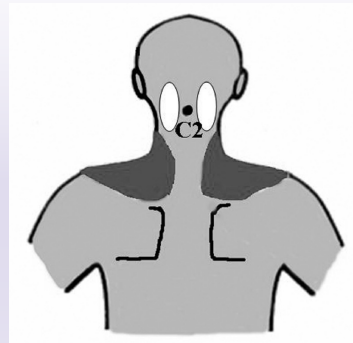
The patient group was comprised of 22 women and 8 men with an average age of 54 years. Each patient had Chiari and syringomyelia confirmed by MRI and underwent decompression surgery with a C-1 laminectomy. For the study, the researchers used x-rays to measure the angles between the occiput in the skull and the top two vertebrae in both the flexed and extended position. Flexion is when the neck is bent forward and extension is when the neck is bent back. They also measured the flexion and extension ROM for the entire cervical region.

In addition to the ROM measurements, the Japanese team classified each patient's Chiari as follows:

- Grade 1: Herniation out of the foramen magnum but above the arch of C-1
- Grade 2: Herniation to the level of the arch of C-1
- Grade 3: Herniation beyond the level of C-1

Syrinxes were classified by their shape: distended, moniliform, slender, or circumscribed. Finally, neck and shoulder pain were assessed (see Figure 1).

Figure 1: Neck (White) & Shoulder (Dark) Pain Locations



Interestingly, the researchers failed to find any significant differences in ROM from pre to post surgery. The average ROM for the occiput - C2 region was 15.5 degrees before surgery and 14.1 degrees after surgery (see Table 1). Similarly, the average C2-C7 ROM was 55.1 degrees before surgery and 52.8 degrees.

The researchers also failed to find any link between the herniation grades and ROM, or the syrinx type and ROM. The results from this study are difficult to interpret. Anecdotally, many Chiari patients, the author included, appear to have limited ROM in the neck. However, actually measuring ROM can be difficult and the results can vary depending on the method used. For example, one study found the average cervical ROM (Occiput - C2) in healthy adults was close to 30 degrees; while a different study found the average was closer to 10 degrees.

For this study, it would have been useful to include healthy subjects so that an average ROM could be obtained using the same measurement technique. Normal ROM can also vary by age. The average age for this group was in the 50's where you might expect some natural limitations to begin developing. It may be that Chiari patients in their 20's and 30's have a more noticeable decrease in neck motion.

It is also important to note that patients with fused vertebrae - as sometimes happens with Chiari - were excluded from this study and that none of the patients required any type of neck stabilization as part of their surgery. Thus, it could be that only a subset of Chiari patients experience limited ROM and those types of patients were not included in this study. Finally, it is not clear how long after surgery the post-op ROM was measured. It can take a considerable amount of time for the flexibility to return, so it would be interesting to see how these patients were doing 1-2 years down the road.

Cervical ROM is an interesting subject for Chiari research, so hopefully researchers will continue to explore this area in an expanded fashion.

Author's Note: *Personally, the ROM of my neck was severely limited prior to decompression surgery. I could not touch my chin to my chest or bend my neck back from neutral at all. Side to side motion was also somewhat limited. It took quite a bit of time (years) after surgery for my neck to become flexible again. While I currently*

so named because of their shape

have good ROM, I still do not like to move my neck quickly or bend it back (extension).

cerebrospinal fluid (CSF) - clear liquid in the brain and spinal cord, acts as a shock absorber

Chiari malformation I - condition where the cerebellar tonsils are displaced out of the skull area into the spinal area, causing compression of brain tissue and disruption of CSF flow

Source

Ono A, Suetsuna F, Ueyama K, Yokoyama T, Aburakawa S, Takeuchi K, Numasawa T, Wada K, Toh S. [Cervical spinal motion before and after surgery in patients with Chiari malformation type I associated with syringomyelia.](#) J Neurosurg Spine. 2007 Nov;7(5):473-7.

Table 1
Pain and ROM Pre & Post Op

	Pre-Op	Post-Op
# w/Neck Pain	10	8
# w/Shoulder Pain	20	18
Occiput - C2 ROM (degrees)	15.5	14.1
C2-C7 ROM (degrees)	55.1	52.8

Notes: None of the differences between pre and post op were statistically significant.

Related C&S News Articles:

[Complex Chiari Cases Have Poorer Outcomes](#)

[Extensive Laminectomy May Increase Risk For Spinal Problems](#)

[Scoliosis Affects Surgical Outcomes In Adults](#)

[Home](#) | [About Us](#) | [Email](#) | [Donate](#) | [Get Involved](#) | [Privacy Policy](#)

Disclaimer: This publication is intended for informational purposes only and may or may not apply to you. The editor and publisher are not doctors and are not engaged in providing medical advice. Always consult a qualified professional for medical care. This publication does not endorse any doctors, procedures, or products.

© 2003-2020 C&S Patient Education Foundation