

## Key Points

1. Tethered cord is a hot topic in the Chiari community
2. Controversy surrounds whether TCS surgery should be performed based only on symptoms
3. While there appears to be a link between TCS and Chiari/SM, it is not well understood
4. Some evidence exists that TCS may actually cause CM/SM in some cases, but other research argues against this
5. Two recent case studies provide more clues about a possible link
6. First case involved a 3 year old girl with a lipomyelomeningocele who developed an acquired Chiari and syrinx, documented by MRI
7. Second case involved a 7 year old boy with a syrinx but no Chiari and symptoms of TCS
8. He underwent TCS surgery which resolved his symptoms and the syrinx

## Definitions

**cervical** - upper region of the spine, neck area

**Chiari 0** - refers to cases where person has Chiari like symptoms but minimal to no tonsillar herniation

**conus medullaris** - the lower end of the spinal cord; when the cord is tethered, the conus sits lower relative to the bony vertebra

**filum terminale** - small thread of tissue at the bottom of the spinal cord; if abnormal can result in TCS

**lipomyelomeningocele** - birth defect where a lump of fatty tissue protrudes from the spinal canal through the spinal column

**occult** - a disease or problem that

## Clues To Link Between Tethered Cord & CM/SM

May 31, 2008 -- Currently there is a lot of discussion in the Chiari community centered around Tethered Cord Syndrome (TCS). Tethered cord refers to when the spinal cord becomes unnaturally fixed which can then lead to neurological problems. Tethering can occur at any level of the spine due to scarring, but TCS usually refers to tethering of the cord at the base. This can be due to a fatty deposit, known as a lipomyelomeningocele, or from an abnormal filum terminale, which is the thread like tissue at the bottom of the spinal cord. Either way, a tethered cord creates traction, or a pulling effect, and can lead to leg weakness and urinary and bowel problems. In the presence of such symptoms, treatment is usually surgical and involves freeing the cord by either cutting the filum or repairing the lipomyelomeningocele defect.

Tethered cord is a relatively new entity, medically speaking, and as such there is still quite a bit of controversy surrounding it. One such area of controversy regards the diagnosis of Tethered Cord Syndrome. Traditionally, tethered cord has been diagnosed radiographically by the position of the conus medullaris at the lower end of the cord. The idea was that if the cord is tethered, the conus would be pulled into a lower position relative to the bony vertebrae of the spine. In most people, the conus is located at the L1-L2 area (the first or second vertebrae of the lumbar region) and in cases where it is found to be lower, there is a good chance the cord is tethered. Another MRI finding which indicates tethered cord is when the filum terminale is found to be unusually thick or fatty. This can indicate that it is not as elastic as it should be and thus creates a downward pull on the cord.

In the past several years however, some surgeons have begun to question the radiographic definition of TCS and speculate that tethering can exist even if the conus is in a normal position. Instead of an MRI, these surgeons rely more on the symptoms and testing of urinary function as an indicator of TCS and operate accordingly. Such cases are often referred to as occult TCS since the tethering is not apparent on MRI.

A second area of controversy involves the relationship, if any, between tethered cord and Chiari/syringomyelia. There are some indications that a significant number of Chiari patients also have TCS, and some surgeons now routinely evaluate Chiari patients for indications of tethered cord either from MRI or symptomatically. When there are indications of TCS, this may be addressed first (or separately) by sectioning the filum terminale before a posterior fossa decompression is performed.

Some researchers have gone further and have suggested that a tethered cord actually causes Chiari, syringomyelia, and scoliosis. However, the evidence for this idea so far is mixed. Ellenbogen reported a case, documented by MRI, of acquired Chiari due to a fatty filum terminale. Similarly, Tubbs has reported that people with lipomyelomeningoceles (which tether the cord) have a high rate of tonsillar herniation. However, attempts to show how the cord tethering would lead to Chiari have not been successful. Specifically, Tubbs also found using cadavers that traction applied to the base of the spinal cord does not move the cerebellar tonsils and the force is dispersed after only a few spinal segments. A study from the 1960's using animals found a similar result.

Now, two recent case reports in the Journal of Neurosurgery: Pediatrics, add more evidence of some type of link between tethered cord and Chiari/syringomyelia. The first case out of Duke University (Waldau et al.) was a 3 year old girl with a large lipomyelomeningocele. The lipo was found at birth but she did not suffer from any problems at first. By the age of 3 however, she was developing urinary problems and was seen by the authors at Duke. They ordered an MRI and in addition to the lipomyelomeningocele found a 12mm Chiari malformation and a large cervical syrinx. Because of her situation, MRIs from her infancy were available and the surgeons found that at the age of 3 months there was no tonsillar herniation and no syrinx (Figure 1).

The girl underwent decompression surgery first, followed by repair of the lipomyelomeningocele. While her legs got stronger, unfortunately she continued to have urinary problems. The authors readily admit that one case does not prove anything, but in combination with the case study cited earlier there are now at least two documented cases (with MRIs) of acquired Chiari most likely due to tethering of the spinal cord. With this in mind, the Duke researchers suggest the development of better animal models to study the effects of the traction caused by a tethered cord during development.

The second recently published case came from the United Kingdom (Caird et al.) and involved a 7 year old boy suffering from progressive fatigue, clumsiness, trouble walking, and incontinence, and lower back pain. An MRI revealed a significant syrinx extending from the C-5 level all the way to T-11, but there was no indication of Chiari or any type of tumor that would cause the syrinx. In addition, the conus was found to be in a normal position, so there was no MRI indication of tethered cord. After much internal debate, the surgeons decided to proceed as if the symptoms were due to tethered cord and sectioned the boy's filum terminale. His back pain and ability to walk improved almost immediately and a follow-up MRI showed his syrinx had shrunk significantly.

Although the authors had been skeptical of the notion of occult TCS, they offer that this case provides objective

is not readily apparent; in other words can not be seen on images

**section** - to cut

**syrinx**  - fluid filled cyst in the spinal cord

**TCS** - Tethered Cord Syndrome; loose name for a spectrum of problems that all result in abnormal traction, or tension on the spinal cord

**traction** - a pulling force

**cerebellar tonsils** - portion of the cerebellum located at the bottom, so named because of their shape

**cerebellum** - part of the brain located at the bottom of the skull, near the opening to the spinal area; important for muscle control, movement, and balance

**cerebrospinal fluid (CSF)** - clear liquid in the brain and spinal cord, acts as a shock absorber

**Chiari malformation I** - condition where the cerebellar tonsils are displaced out of the skull area into the spinal area, causing compression of brain tissue and disruption of CSF flow

**decompression surgery** - general term used for any of several surgical techniques employed to create more space around a Chiari malformation and to relieve compression

**syringomyelia** - condition where a fluid filled cyst forms in the spinal cord

## Source

**Sources:** Waldau B, Grant G, Fuchs H. [Development of an acquired Chiari malformation Type I in the setting of an untreated lipomyelomeningocele. Case report.](#) J Neurosurg Pediatrics. 2008 Feb;1(2):164-6

Caird J, Flynn P, McConnell RS. [Significant clinical and radiological resolution of a spinal cord syrinx following the release of a tethered cord in a patient with an anatomically normal conus medullaris.](#) J Neurosurg Pediatrics. 2008 May;1(5):396-8

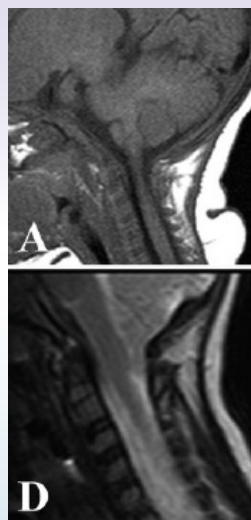
evidence (with the resolution of the syrinx) that there was tethering of the cord which was not apparent on MRI. It also points to a possible role of tethered cord in the development of a syrinx in some cases. Based on this, the scientists posed several questions:

- In this case was a Chiari 0 actually present?
- Can tethering play a role in syrinx formation even if the conus is in a normal position?
- Would a study to determine conus position in patients with syringomyelia and or Chiari reveal anything?
- Would a study involving tethered cord surgery for patients with minimal herniation be ethically feasible?

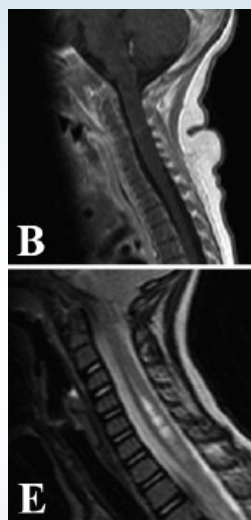
More questions can of course be added to this list, such as is there a relationship between patients with tethered cord symptoms and posterior fossa volume, or do they represent two distinct patient groups and potential causes of Chiari?

While the current picture appears muddled, it is encouraging that researchers are asking these questions, which hopefully will lead to answers sooner rather than later.

**Figure 1: MRI Evidence Documenting Acquired Chiari**



**Note:** Picture A shows patient at 3 months old with no Chiari; Picture D shows the same patient at 3 years with a 12 mm herniation



**Note:** Picture B, at 3 months, shows no signs of a syrinx; Picture E, at 3 years, shows a significant syrinx in the cervical region

## Related C&S News Articles:

[Possible Biomarkers Found For Tethered Cord](#)

[Chiari Linked To Lipomyelomeningocele](#)

[New Study Casts Doubt On Tethered Cord Causing Chiari](#)

[MRI Documents Acquired Chiari Due To Fatty Filum](#)

[Minimal Tethered Cord Shows Abnormal Anatomy](#)

[Controversy Surrounds Occult Tethered Cord Syndrome](#)

[Home](#) | [About Us](#) | [Email](#) | [Donate](#) | [Get Involved](#) | [Privacy Policy](#)

---

**Disclaimer:** This publication is intended for informational purposes only and may or may not apply to you. The editor and publisher are not doctors and are not engaged in providing medical advice. Always consult a qualified professional for medical care. This publication does not endorse any doctors, procedures, or products.

© 2003-2020 C&S Patient Education Foundation