

### Key Points

1. There are many options available for dural graft materials, including collagen based, cadavers, autografts, and synthetic materials
2. An ideal graft material must be easy to handle, watertight, and not lead to scars and adhesions
3. Study directly compared using autografts and a synthetic graft for Chiari surgery in 67 children
4. Looked at surgical complications, MRI based outcomes, and clinical outcomes
5. Found that the group with autografts had more CSF blockages around the graft area
6. Also found that 4 children in the autograft group had to undergo additional surgery, compared to none in the synthetic group
7. While both groups showed good improvement in syrinx size, the improvement occurred sooner in the synthetic graft group
8. The synthetic graft appears to produce good results, but the study structure does not allow strong conclusions to be drawn

### Definitions

**autograft** - a dural graft which is taken from the patient's own tissue

**bovine** - from a cow

**cadaver** - the body of a dead person

**collagen** - connective tissue

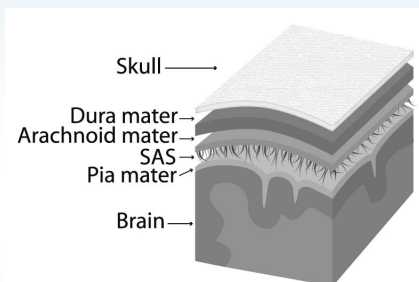
**dura** - outer layer of the covering of the brain and spine

**duraplasty** - surgical technique where the dura is expanded by cutting it open and inserting a patch

## Synthetic Graft May Be More Effective Than Autograft

**November 30, 2008** -- A recent study from Johns Hopkins has found that a synthetic dural graft performed better than grafts taken from the patient's own tissue (autograft) in Chiari surgeries.

The dura (Figure 2-7, picture taken from *Conquer Chiari: A Patient's Guide*), is the thick, outer most layer of the meninges, which cover the brain and spinal cord. The dura is often opened as part of Chiari surgery in an attempt to relieve pressure and create more space for the flow of cerebrospinal fluid. The procedure, known as a duraplasty, also involves sewing a patch, or graft, into the dura to make it bigger.



**Figure 2-7**

Over the years, surgeons have tried many different graft materials, including ones taken from cows and human cadavers. Today, two of the more popular options are to use tissue from the patient's own body, known as an autograft, and synthetic dura substitutes. The ideal material for a dural patch must be flexible, easy to handle for the surgeon, watertight to prevent CSF leaks, and minimize scarring and adhesions. Scars and adhesions from dural patches is one of the main contributors to failed Chiari surgeries. While there is some research comparing graft materials, the choice usually comes down to an individual surgeon's preferences, and is often based on their own experience with different graft types.

The Hopkins' study, published in the on-line edition of *Childs Nervous System* in September, 2008, directly compared the authors' experience with using autografts versus a synthetic graft from W.L. Gore. Specifically, they looked at surgical complications, post-surgical reduction in CSF flow near the patch, MRI evidence of a pseudomeningocele, syrinx improvement, symptom recurrence, and the need for reoperation.

The research involved 67 children who underwent Chiari surgery performed by two surgeons. The surgical techniques were very similar, however one surgeon used an autograft (40 patients) and the other surgeon used the synthetic graft (27 patients). The children were given MRIs both 3 months and 1 year after surgery. The medical records were reviewed to identify patients whose symptoms came back and those who needed additional surgery. Clinically, the patients in both groups exhibited similar symptoms prior to surgery, such as headaches, sensory disturbances, weakness, etc.

In terms of surgical complications, the researchers found no difference based on type of graft. The same was true for length of hospital stay. However, when the MRI records were reviewed, some key differences emerged (Figure 1). Although the number of pseudomeningoceles was not significantly different between the two groups, twenty-one percent of the children who received autografts showed decreased CSF flow in the area of the patch compared to none in the synthetic group. This is one of the key problems with graft materials, namely that adhesions and scarring can disrupt the flow of CSF. In addition, although both groups showed good improvement in the reduction of syrinx sizes, on average, the synthetic graft group improved months before the autograft group.

Clinically, about the same number of patients experienced mild to moderate symptom recurrence in each group (Figure 2). However, while there were no revision surgeries in the synthetic group, 10% of the autograft group underwent additional surgery due to symptom recurrence. The need for additional surgery is perhaps the most directly relevant outcome measure from a patient's point of view, so the fact that there were no revisions in the synthetic graft group is impressive.

While the results from this study do indicate that the graft from W. L. Gore can be used with good results, because of the design of the study, it can not be stated conclusively that it is superior to autografts. To truly compare graft materials, patients would have to be randomly assigned to which type of graft they receive and the work should be done by only one surgeon. The fact that in this study each surgeon only used one type of graft means that the results could reflect the relative skill of the individual surgeons. In addition, it should be noted that one of the authors is a consultant to W. L. Gore.

**meninges** - layered covering of the brain and spinal cord

**phase contrast MRI** - type of MRI which can show CSF flow

**pseudomeningocele** - complication from surgery where an abnormal collection of CSF forms and can bulge into the surrounding tissue; some cases require surgical repair

**radiographic** - refers to medical imaging

**cerebellar tonsils** - portion of the cerebellum located at the bottom, so named because of their shape

**cerebrospinal fluid (CSF)** - clear liquid in the brain and spinal cord, acts as a shock absorber

**Chiari malformation I** - condition where the cerebellar tonsils are displaced out of the skull area into the spinal area, causing compression of brain tissue and disruption of CSF flow

**decompression surgery** - general term used for any of several surgical techniques employed to create more space around a Chiari malformation and to relieve compression

**syringomyelia** - condition where a fluid filled cyst forms in the spinal cord

## Source

**Source:** [Suboccipital decompression for Chiari I malformation: outcome comparison of duraplasty with expanded polytetrafluoroethylene dural substitute versus pericranial autograft](#). Attenello FJ, McGirt MJ, Garcés-Ambrossi GL, Chaichana KL, Carson B, Jallo GI. Childs Nerv Syst. 2008 Sep 4. [Epub ahead of print]

**Figure 1: Radiographic Outcomes, Synthetic vs Autograft**

	Synthetic	Autograft	Sig?
Pseudo.	24%	11%	N
Loss of CSF Space	0%	21%	Y
Syrinx Improvement	80%	52%	N

**Figure 2: Clinical Outcomes, Synthetic vs Autograft**

	Synthetic	Autograft	Sig?
Symptom Recur.	11%	27%	N
Surgical Revision	0%	10%	N*

**Notes:** **Sig?** refers to whether the difference was statistically significant, meaning it is unlikely to be due to chance. The surgical revisions difference approached statistical significance.

## Related C&S News Articles:

[Meta-Analysis Compares Duraplasty To No Duraplasty](#)

[Study Shows Few CSF Related Complications With Autologous Duraplasty](#)

[New Dural Patch Found To Be Safe And Effective](#)

[Do You Know What's In Your Head? Study Compares Dural Graft Materials](#)

[Home](#) | [About Us](#) | [Email](#) | [Donate](#) | [Get Involved](#) | [Privacy Policy](#)

**Disclaimer:** This publication is intended for informational purposes only and may or may not apply to you. The editor and publisher are not doctors and are not engaged in providing medical advice. Always consult a qualified professional for medical care. This publication does not endorse any doctors, procedures, or products.