

Key Points

1. The cognitive effects of Chiari are just beginning to be studied
2. While there is indirect evidence that Chiari can cause cognitive problems, there is little direct evidence
3. Patients with Chiari II have been noted to have problems with learning and memory
4. The limbic system in the brain is thought to be involved in learning and memory
5. Researchers used a special MRI technique to create images of specific nerve fiber paths in the limbic system in patients with Chiari II
6. Patients also underwent intelligence, learning, and memory tests
7. Found high rate of abnormalities of the limbic system and deficits in memory and learning
8. Abnormal fornix was correlated with nonverbal memory problems
9. Not clear if this applies to Chiari I

Definitions

Chiari II - more severe form of Chiari, associated with spina bifida, where in addition to the cerebellar tonsils, the brainstem is herniated

cingulum - a bundle of fibers which encircle the corpus callosum

corpus callosum - a bundle of 200-300 million nerve fibers that connect the left and right hemispheres of the brain

diffusion tensor MRI - specific type of MRI which can be used to image specific nerve fibers

fiber tract reconstruction - method of mapping the specific nerve fiber tracts in the nervous system

Chiari Related Memory & Learning Problems

August 20, 2006 -- While Chiari patients have wondered for years whether, and how, Chiari might affect thinking, learning, and memory, it is only recently that some researchers have turned their attention to this topic. There is ample indirect evidence that Chiari has the potential to affect cognition.

Research involving damage to the cerebellum - not related to Chiari - has shown significant deficits in intelligence tests due to problems such as tumors.

In addition, Chiari has the potential to affect more than just one part of the brain. The effects of blocking the natural flow of spinal fluid on other parts of the brain are not known. What has been shown, however, is that a long-term increase in intracranial pressure, which is common with Chiari, can have far-reaching cognitive effects.

In the June issue of Chiari & Syringomyelia News, we reported the results of a study which focused directly on the impact of Chiari II (associated with spina bifida) on learning and memory. Now, a research team (Vachha, Adams, Rollins) from the University of Texas Southwestern Medical Center, in Dallas, has used cutting edge technology to delve further into this important topic.

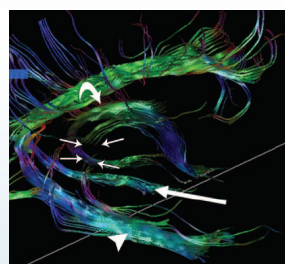
What they found, namely a connection between learning and memory problems and abnormalities of specific brain structures, was reported in the July, 2006 issue of the journal, Radiology.

The research team prospectively recruited children with Chiari II to undergo advanced imaging studies and well established cognitive testing. To participate in the study, the children had to have been treated for hydrocephalus before 1 year of age, be able to participate in the verbal testing (speak English), and not suffer from uncontrolled seizures. Children with a history of recent shunt malfunctions, disabilities that would interfere with the cognitive testing, a diagnosis of ADHD or mental retardation, did not speak English, or were too young were excluded from the study. Based on this criteria, 13 children participated in the imaging portion of the study, but only 9 underwent the memory and learning testing as well (due to various reasons).

For the imaging studies, a newer technique, known as diffusion tensor MRI, was used to visualize the structures of the limbic system. The limbic system, in the brain, is widely recognized to control feelings and emotion, but is also thought to play a critical role in memory and learning.

From the MRI images, sophisticated software can be used to actually create images of nerve fiber pathways in the brain (see Figure 1). This is known as Fiber Tract Reconstruction, and from these images, an experienced neuroradiologist can detect even minor structural abnormalities.

Figure 1
Example Fiber Tract Reconstruction Image



Note: Sagittal FT reconstruction image in 14-year-old girl with general memory and learning impairment. Defect in right crus of the fornix (short straight arrows) and intact left fornix (curved arrow) are observed. Temporal segment of left cingulum (long straight arrow) is attenuated compared with the normal right temporal segment (arrowhead).

The cognitive testing was comprised of general intelligence tests, along with tests designed to create a global memory index score and a global learning index score. Subcategories included both verbal and nonverbal immediate and delayed recall. Specific tasks included (but were not limited to): immediately recalling lists of word pairs or a story; recalling word pairs after a period of time; reconstructing dot patterns; and facial recognition tasks.

As stated previously, 13 children participated in the imaging portion of the study. When the images were

fornix - bundle of nerve fibers connecting two parts of the brain

hydrocephalus - condition characterized by an abnormal collection of CSF in the brain; commonly associated with Chiari II

limbic system - a set of brain structures involved in controlling feelings and emotion; also thought to play a role in memory and learning

spina bifida - congenital disease where the spinal column is not closed properly; myelomeningocele

tract - nerve pathway

Common Chiari Terms

cerebellar tonsils - portion of the cerebellum located at the bottom, so named because of their shape

cerebellum - part of the brain located at the bottom of the skull, near the opening to the spinal area; important for muscle control, movement, and balance

cerebrospinal fluid (CSF) - clear liquid in the brain and spinal cord, acts as a shock absorber

Chiari malformation I - condition where the cerebellar tonsils are displaced out of the skull area into the spinal area, causing compression of brain tissue and disruption of CSF flow

decompression surgery - general term used for any of several surgical techniques employed to create more space around a Chiari malformation and to relieve compression

Source

Source: Vachha B, Adams RC, Rollins NK.
[Limbic tract anomalies in pediatric myelomeningocele and Chiari II malformation: anatomic correlations with memory and learning--initial investigation.](#)
Radiology. 2006 Jul;240(1):194-202.

reviewed by a specialist (who was not aware of the cognitive testing results) he found that 85% of the patients had identifiable abnormalities of the limbic system (see Table 1). Two specific nerve bundles, which are thought to connect different components of the limbic system, the fornix and cingulum were identified specifically as problem areas. In fact, 9 of 13 children had abnormalities of fornix and 10 of 13 had abnormalities of the cingulum.

Table 1
Limbic System Abnormalities Found Using FT Reconstruction (13 Patients)

Abnormality	# of Patients	% of Patients
Fornix	9	69
Cingulum	10	77
Any	11	85

Due to various reasons, only 9 of the 13 children were able to participate in the cognitive evaluations, but the results from this smaller group were very interesting. On average, the group scored within the normal range for overall intelligence, but showed marked deficits in memory and learning.

Specifically, 6 of the 9 children demonstrated general memory deficits. When the team looked at the imaging results for these six, they found that all of them had evidence of an abnormal fornix and 4 of the 6 showed abnormalities of the cingulum. Similarly, 4 of the 9 children scored low on the learning index, and all four of these children had an abnormal fornix as well. Three-fourths of this group showed abnormalities of the cingulum.

When the researchers looked more closely at the data, they found the strongest connection was between an abnormal fornix and problems with nonverbal immediate recall. While the evidence of a link between limbic system abnormalities in Chiari II and memory and learning problems is compelling, the authors point out that it is difficult to account for the effects of hydrocephalus. However, researchers in the past have argued that children with average overall intelligence are unlikely to suffer from global negative effects of hydrocephalus.

In discussing the specific nature of the abnormalities that were so prevalent in the study group, the authors speculate that they could be a result of neurons not migrating properly during development. They also believe that this might be linked with the core problem of spina bifida, which would limit the applicability of these findings to Chiari II.

It should also be pointed out that the authors articulate a number of potential problems with this study and stress it is a preliminary investigation. Still, for an anxious Chiari community, even some preliminary work is better than nothing.

Related C&S News Articles:

[Study Identifies Cognitive Impact Of Chiari II](#)

[Abnormal EEG Results Indicate Chiari's Subtle Effects](#)

[What Is Cerebellar Affective Disorder And What Does It Mean For Chiari](#)

[Damage To Cerebellum Affects Cognitive Ability In Children](#)

consult a qualified professional for medical care. This publication does not endorse any doctors, procedures, or products.

© 2003-2020 C&S Patient Education Foundation